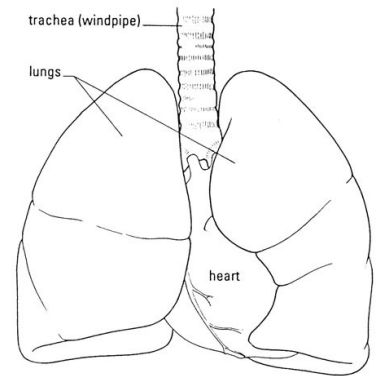


LAB - Dissection of Sheep's Pluck

Purpose: Today we will be exploring the structures of the respiratory system. We will also be examining how our lungs move as we breathe. Lastly, we will be describing how the structure of the lungs relate to how we breathe.

Procedure:

1. When handling the sheep's pluck, make sure to wear disposable gloves. Aprons and goggles are also available for additional protection.
2. Examine your specimen. Describe the color, shape, size, and feel of the specimen.
3. What organs/body parts are included in your specimen?
4. Identify the trachea. Is the trachea stiff or flexible? What allows the trachea to stay open and bend? Why is this important?
5. Try to inflate the lungs and observe how they respond. Do not breathe directly into the trachea to do this! Insert a length of rubber tubing into the trachea and attach it to a bellows or foot pump to inflate the lungs and then watch them deflate. It is best not to breathe through the tube into the lungs yourself because of the elastic recoil of the lung tissue: you might inhale a blast of rather unpleasant air!
 - a. What happened to the lungs when air was forced into them?
 - b. Do you think there is a limit to how much air can be pumped into the lungs? Explain your answer
5. Start of cut down the trachea with your dissecting scissors. Does the trachea stay as one tube or does it split as it enters the lung?



6. If the larynx is still attached to your lungs, try forcing air through the larynx while you squeeze it tight. As air moves past the skin and cords in the larynx it may make a noise.

Discuss how similar this is to the noise the animal makes in life.

7. Cut a small piece of spongy lung tissue to examine more closely.

- Are the lungs hollow bags or spongy? _____
- What does the lung tissue look like where you cut into it? _____
- Drop the piece of lung into a beaker of water. Does the piece sink or float? _____
- What does the answer to part c indicate? _____

8. Now let's examine the heart as review. Use a scalpel to remove a portion of this layer and expose the *myocardium* beneath.

- Note the abundance of fat along the paths of various blood vessels. This adipose tissue occurs in the loose connective tissue that underlies the visceral pericardium.
- Identify the following: ***Right Atrium, Right Ventricle, Pulmonary Artery, Left Atrium, Left Ventricle, and the Aorta***

9. Examine the dorsal surface of the heart (the side closest to your back).

- Locate the stumps of two relatively thin-walled blood vessels that enter the right atrium.
- Demonstrate this connection by passing a slender probe through them.
- The upper vessel is the *superior vena cava*, and the lower one is the *inferior vena cava*.

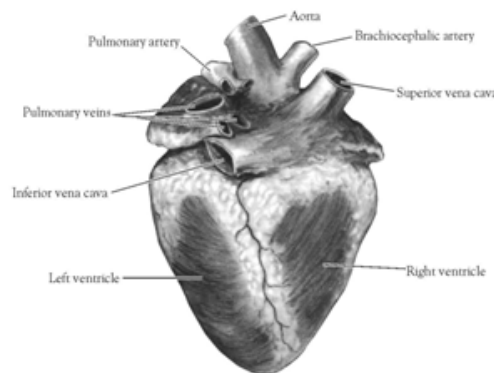


Figure 2. Heart (Posterior View)

10. Open the *right atrium*. To do this, follow these steps:

- Insert a blade of the scissors into the *superior vena cava* and cut downward through the atrial wall.
- Open the chamber, locate the *tricuspid valve* and examine its cusps.
- Run some water through the tricuspid valve to fill the chamber of the *right ventricle*.
- Gently squeeze the ventricles and watch the cusps of the valve as the water moves up against them.

11. Open the *right ventricle* as follows:

- a. Continue cutting downward through the *tricuspid valve* and the *right ventricular wall* until you reach the apex of the heart.
- b. Find the opening to the *pulmonary trunk* and use the scissors to cut upward through the wall of the *right ventricle*. Follow the pulmonary trunk until you have exposed the *pulmonary valve*.
- c. Examine the valve and its cusps.

12. Open the left side of the heart. To do this, follow these steps:

- a. Insert the blade of the scissors through the wall of the *left atrium* and cut downward to the apex of the heart.
- b. Open the *left atrium* and locate the four openings of the *pulmonary veins*. Pass a slender probe through each opening and locate the stump of its vessel.
- c. Examine the *bicuspid valve* (mitral valve) and its cusps.
- d. Also examine the *left ventricle* and compare the thickness of its wall with that of the *right ventricle*.

13. Locate the *aorta*, which leads away from the *left ventricle*, and proceed as follows:

- a. Compare the thickness of the *aortic wall* with that of the *pulmonary trunk*.
- b. Use scissors to cut along the length of the *aorta* to expose the *aortic valve* at its base.
- c. Examine the cusps of the valve and locate the openings of the *coronary arteries* just distal to them.

Questions

1. How many chambers are found in the mammalian heart? List these chambers.
2. Which chambers are the pumping chambers of the heart?
3. Which chambers are the receiving chambers of the heart?

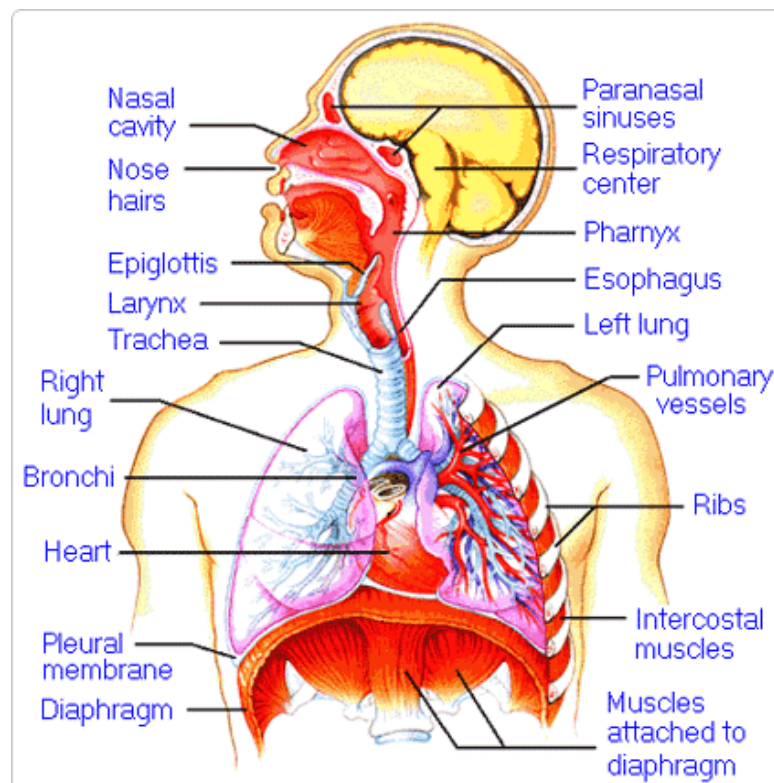
4. How do the walls of the atria compare with the walls of the ventricles and why are they different?

5. What is the purpose of heart valves?

6. Vessels that carry blood away from the heart are called _____, while _____ carry blood toward the heart.

7. Which artery is the largest and why?

8. How are the heart and lungs' function(s) related?

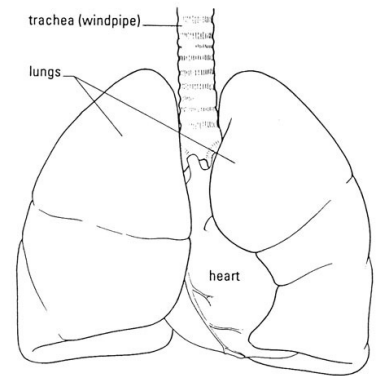


LAB - Dissection of Sheep's Pluck

Purpose: Today we will be exploring the structures of the respiratory system. We will also be examining how our lungs move as we breathe. Lastly, we will be describing how the structure of the lungs relate to how we breathe.

Procedure:

1. When handling the sheep's pluck, make sure to wear disposable gloves. Aprons and goggles are also available for additional protection.
2. Examine your specimen. Describe the color, shape, size, and feel of the specimen.
3. What organs/body parts are included in your specimen?
4. Identify the trachea. Is the trachea stiff or flexible? What allows the trachea to stay open and bend? Why is this important?
5. Try to inflate the lungs and observe how they respond. Do not breathe directly into the trachea to do this! Insert a length of rubber tubing into the trachea and attach it to a bellows or foot pump to inflate the lungs and then watch them deflate. It is best not to breathe through the tube into the lungs yourself because of the elastic recoil of the lung tissue: you might inhale a blast of rather unpleasant air!
 - a. What happened to the lungs when air was forced into them?
 - b. Do you think there is a limit to how much air can be pumped into the lungs? Explain your answer
5. Start of cut down the trachea with your dissecting scissors. Does the trachea stay as one tube or does it split as it enters the lung?



6. If the larynx is still attached to your lungs, try forcing air through the larynx while you squeeze it tight. As air moves past the skin and cords in the larynx it may make a noise.

Discuss how similar this is to the noise the animal makes in life.

7. Cut a small piece of spongy lung tissue to examine more closely.

- a. Are the lungs hollow bags or spongy? _____
- b. What does the lung tissue look like where you cut into it? _____
- c. Drop the piece of lung into a beaker of water. Does the piece sink or float? _____
- d. What does the answer to part c indicate? _____

8. Now let's examine the heart as review. Use a scalpel to remove a portion of this layer and expose the *myocardium* beneath.

- Note the abundance of fat along the paths of various blood vessels. This adipose tissue occurs in the loose connective tissue that underlies the visceral pericardium.
- Identify the following: ***Right Atrium, Right Ventricle, Pulmonary Artery, Left Atrium, Left Ventricle, and the Aorta***

9. Examine the dorsal surface of the heart (the side closest to your back).

- Locate the stumps of two relatively thin-walled blood vessels that enter the right atrium.
- Demonstrate this connection by passing a slender probe through them.
- The upper vessel is the *superior vena cava*, and the lower one is the *inferior vena cava*.

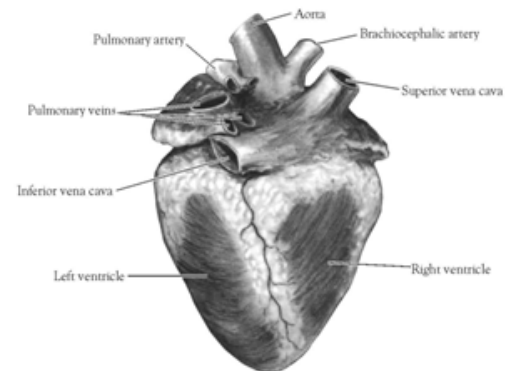


Figure 2. Heart (Posterior View)

10. Open the *right atrium*. To do this, follow these steps:

- a. Insert a blade of the scissors into the *superior vena cava* and cut downward through the atrial wall.
- b. Open the chamber, locate the *tricuspid valve* and examine its cusps.
- c. Run some water through the tricuspid valve to fill the chamber of the *right ventricle*.
- d. Gently squeeze the ventricles and watch the cusps of the valve as the water moves up against them.

11. Open the *right ventricle* as follows:

- a. Continue cutting downward through the *tricuspid valve* and the *right ventricular wall* until you reach the apex of the heart.
- b. Find the opening to the *pulmonary trunk* and use the scissors to cut upward through the wall of the *right ventricle*. Follow the pulmonary trunk until you have exposed the *pulmonary valve*.
- c. Examine the valve and its cusps.

12. Open the left side of the heart. To do this, follow these steps:

- a. Insert the blade of the scissors through the wall of the *left atrium* and cut downward to the apex of the heart.
- b. Open the *left atrium* and locate the four openings of the *pulmonary veins*. Pass a slender probe through each opening and locate the stump of its vessel.
- c. Examine the *bicuspid valve* (mitral valve) and its cusps.
- d. Also examine the *left ventricle* and compare the thickness of its wall with that of the *right ventricle*.

13. Locate the *aorta*, which leads away from the *left ventricle*, and proceed as follows:

- a. Compare the thickness of the *aortic wall* with that of the *pulmonary trunk*.
- b. Use scissors to cut along the length of the *aorta* to expose the *aortic valve* at its base.
- c. Examine the cusps of the valve and locate the openings of the *coronary arteries* just distal to them.

Questions

1. How many chambers are found in the mammalian heart? List these chambers.
2. Which chambers are the pumping chambers of the heart?
3. Which chambers are the receiving chambers of the heart?

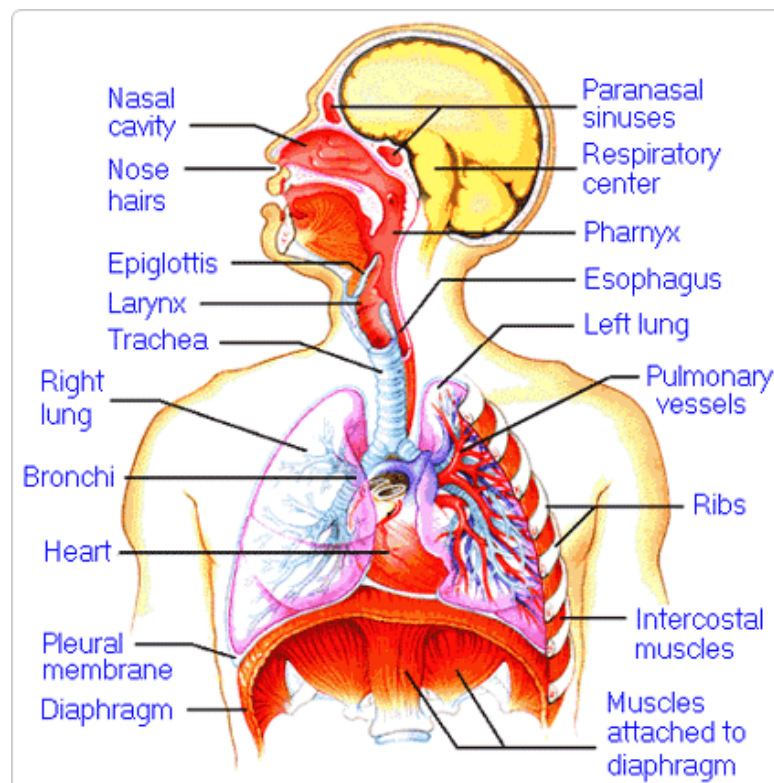
4. How do the walls of the atria compare with the walls of the ventricles and why are they different?

5. What is the purpose of heart valves?

6. Vessels that carry blood away from the heart are called _____, while _____ carry blood toward the heart.

7. Which artery is the largest and why?

8. How are the heart and lungs' function(s) related?

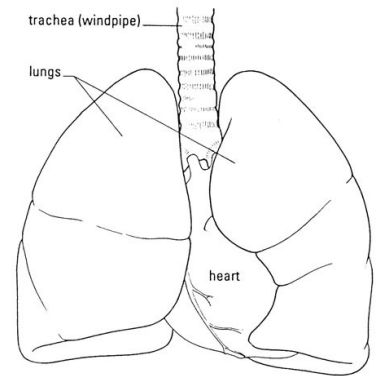


LAB - Dissection of Sheep's Pluck

Purpose: Today we will be exploring the structures of the respiratory system. We will also be examining how our lungs move as we breathe. Lastly, we will be describing how the structure of the lungs relate to how we breathe.

Procedure:

1. When handling the sheep's pluck, make sure to wear disposable gloves. Aprons and goggles are also available for additional protection.
2. Examine your specimen. Describe the color, shape, size, and feel of the specimen.
3. What organs/body parts are included in your specimen?
4. Identify the trachea. Is the trachea stiff or flexible? What allows the trachea to stay open and bend? Why is this important?
5. Try to inflate the lungs and observe how they respond. Do not breathe directly into the trachea to do this! Insert a length of rubber tubing into the trachea and attach it to a bellows or foot pump to inflate the lungs and then watch them deflate. It is best not to breathe through the tube into the lungs yourself because of the elastic recoil of the lung tissue: you might inhale a blast of rather unpleasant air!
 - a. What happened to the lungs when air was forced into them?
 - b. Do you think there is a limit to how much air can be pumped into the lungs? Explain your answer
5. Start of cut down the trachea with your dissecting scissors. Does the trachea stay as one tube or does it split as it enters the lung?



6. If the larynx is still attached to your lungs, try forcing air through the larynx while you squeeze it tight. As air moves past the skin and cords in the larynx it may make a noise.

Discuss how similar this is to the noise the animal makes in life.

7. Cut a small piece of spongy lung tissue to examine more closely.

- Are the lungs hollow bags or spongy? _____
- What does the lung tissue look like where you cut into it? _____
- Drop the piece of lung into a beaker of water. Does the piece sink or float? _____
- What does the answer to part c indicate? _____

8. Now let's examine the heart as review. Use a scalpel to remove a portion of this layer and expose the *myocardium* beneath.

- Note the abundance of fat along the paths of various blood vessels. This adipose tissue occurs in the loose connective tissue that underlies the visceral pericardium.
- Identify the following: ***Right Atrium, Right Ventricle, Pulmonary Artery, Left Atrium, Left Ventricle, and the Aorta***

9. Examine the dorsal surface of the heart (the side closest to your back).

- Locate the stumps of two relatively thin-walled blood vessels that enter the right atrium.
- Demonstrate this connection by passing a slender probe through them.
- The upper vessel is the *superior vena cava*, and the lower one is the *inferior vena cava*.

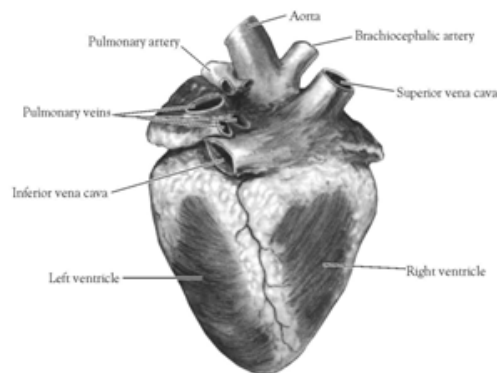


Figure 2. Heart (Posterior View)

10. Open the *right atrium*. To do this, follow these steps:

- Insert a blade of the scissors into the *superior vena cava* and cut downward through the atrial wall.
- Open the chamber, locate the *tricuspid valve* and examine its cusps.
- Run some water through the tricuspid valve to fill the chamber of the *right ventricle*.
- Gently squeeze the ventricles and watch the cusps of the valve as the water moves up against them.

11. Open the *right ventricle* as follows:

- a. Continue cutting downward through the *tricuspid valve* and the *right ventricular wall* until you reach the apex of the heart.
- b. Find the opening to the *pulmonary trunk* and use the scissors to cut upward through the wall of the *right ventricle*. Follow the pulmonary trunk until you have exposed the *pulmonary valve*.
- c. Examine the valve and its cusps.

12. Open the left side of the heart. To do this, follow these steps:

- a. Insert the blade of the scissors through the wall of the *left atrium* and cut downward to the apex of the heart.
- b. Open the *left atrium* and locate the four openings of the *pulmonary veins*. Pass a slender probe through each opening and locate the stump of its vessel.
- c. Examine the *bicuspid valve* (mitral valve) and its cusps.
- d. Also examine the *left ventricle* and compare the thickness of its wall with that of the *right ventricle*.

13. Locate the *aorta*, which leads away from the *left ventricle*, and proceed as follows:

- a. Compare the thickness of the *aortic wall* with that of the *pulmonary trunk*.
- b. Use scissors to cut along the length of the *aorta* to expose the *aortic valve* at its base.
- c. Examine the cusps of the valve and locate the openings of the *coronary arteries* just distal to them.

Questions

1. How many chambers are found in the mammalian heart? List these chambers.
2. Which chambers are the pumping chambers of the heart?
3. Which chambers are the receiving chambers of the heart?

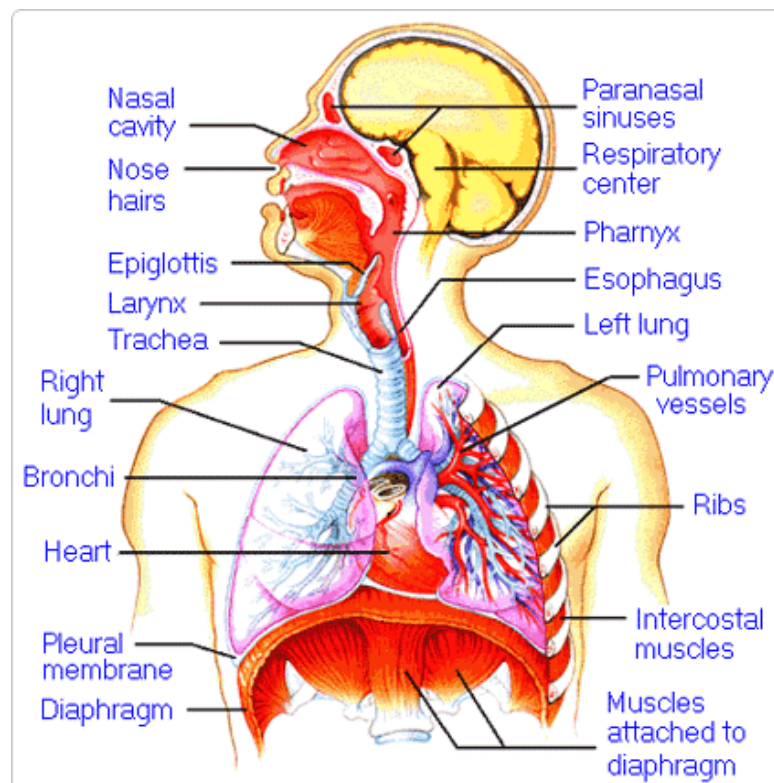
4. How do the walls of the atria compare with the walls of the ventricles and why are they different?

5. What is the purpose of heart valves?

6. Vessels that carry blood away from the heart are called _____, while _____ carry blood toward the heart.

7. Which artery is the largest and why?

8. How are the heart and lungs' function(s) related?

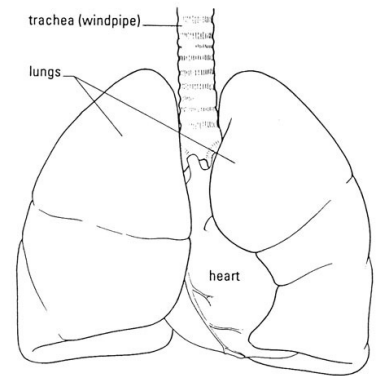


LAB - Dissection of Sheep's Pluck

Purpose: Today we will be exploring the structures of the respiratory system. We will also be examining how our lungs move as we breathe. Lastly, we will be describing how the structure of the lungs relate to how we breathe.

Procedure:

1. When handling the sheep's pluck, make sure to wear disposable gloves. Aprons and goggles are also available for additional protection.
2. Examine your specimen. Describe the color, shape, size, and feel of the specimen.
3. What organs/body parts are included in your specimen?
4. Identify the trachea. Is the trachea stiff or flexible? What allows the trachea to stay open and bend? Why is this important?
5. Try to inflate the lungs and observe how they respond. Do not breathe directly into the trachea to do this! Insert a length of rubber tubing into the trachea and attach it to a bellows or foot pump to inflate the lungs and then watch them deflate. It is best not to breathe through the tube into the lungs yourself because of the elastic recoil of the lung tissue: you might inhale a blast of rather unpleasant air!
 - a. What happened to the lungs when air was forced into them?
 - b. Do you think there is a limit to how much air can be pumped into the lungs? Explain your answer
5. Start of cut down the trachea with your dissecting scissors. Does the trachea stay as one tube or does it split as it enters the lung?



6. If the larynx is still attached to your lungs, try forcing air through the larynx while you squeeze it tight. As air moves past the skin and cords in the larynx it may make a noise.

Discuss how similar this is to the noise the animal makes in life.

7. Cut a small piece of spongy lung tissue to examine more closely.

- Are the lungs hollow bags or spongy? _____
- What does the lung tissue look like where you cut into it? _____
- Drop the piece of lung into a beaker of water. Does the piece sink or float? _____
- What does the answer to part c indicate? _____

8. Now let's examine the heart as review. Use a scalpel to remove a portion of this layer and expose the *myocardium* beneath.

- Note the abundance of fat along the paths of various blood vessels. This adipose tissue occurs in the loose connective tissue that underlies the visceral pericardium.
- Identify the following: ***Right Atrium, Right Ventricle, Pulmonary Artery, Left Atrium, Left Ventricle, and the Aorta***

9. Examine the dorsal surface of the heart (the side closest to your back).

- Locate the stumps of two relatively thin-walled blood vessels that enter the right atrium.
- Demonstrate this connection by passing a slender probe through them.
- The upper vessel is the *superior vena cava*, and the lower one is the *inferior vena cava*.

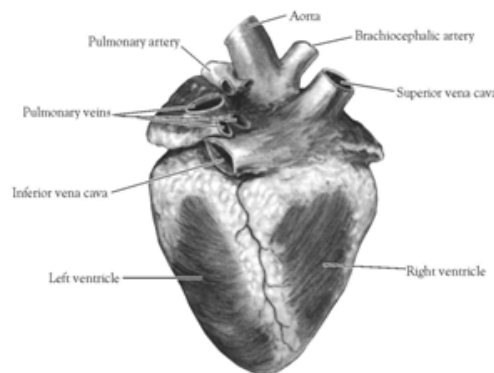


Figure 2. Heart (Posterior View)

10. Open the *right atrium*. To do this, follow these steps:

- Insert a blade of the scissors into the *superior vena cava* and cut downward through the atrial wall.
- Open the chamber, locate the *tricuspid valve* and examine its cusps.
- Run some water through the tricuspid valve to fill the chamber of the *right ventricle*.
- Gently squeeze the ventricles and watch the cusps of the valve as the water moves up against them.

11. Open the *right ventricle* as follows:

- a. Continue cutting downward through the *tricuspid valve* and the *right ventricular wall* until you reach the apex of the heart.
- b. Find the opening to the *pulmonary trunk* and use the scissors to cut upward through the wall of the *right ventricle*. Follow the pulmonary trunk until you have exposed the *pulmonary valve*.
- c. Examine the valve and its cusps.

12. Open the left side of the heart. To do this, follow these steps:

- a. Insert the blade of the scissors through the wall of the *left atrium* and cut downward to the apex of the heart.
- b. Open the *left atrium* and locate the four openings of the *pulmonary veins*. Pass a slender probe through each opening and locate the stump of its vessel.
- c. Examine the *bicuspid valve* (mitral valve) and its cusps.
- d. Also examine the *left ventricle* and compare the thickness of its wall with that of the *right ventricle*.

13. Locate the *aorta*, which leads away from the *left ventricle*, and proceed as follows:

- a. Compare the thickness of the *aortic wall* with that of the *pulmonary trunk*.
- b. Use scissors to cut along the length of the *aorta* to expose the *aortic valve* at its base.
- c. Examine the cusps of the valve and locate the openings of the *coronary arteries* just distal to them.

Questions

1. How many chambers are found in the mammalian heart? List these chambers.
2. Which chambers are the pumping chambers of the heart?
3. Which chambers are the receiving chambers of the heart?

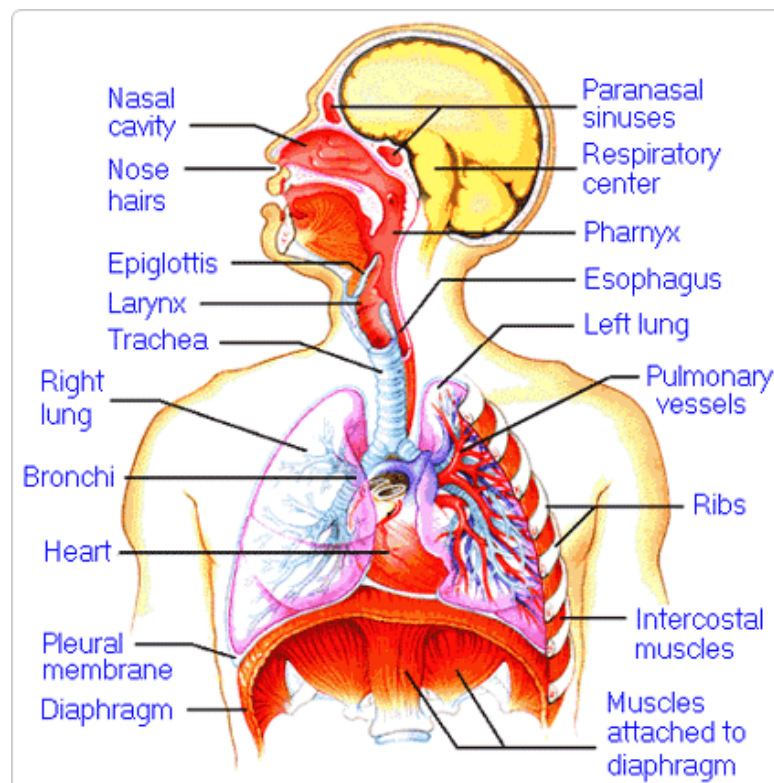
4. How do the walls of the atria compare with the walls of the ventricles and why are they different?

5. What is the purpose of heart valves?

6. Vessels that carry blood away from the heart are called _____, while _____ carry blood toward the heart.

7. Which artery is the largest and why?

8. How are the heart and lungs' function(s) related?

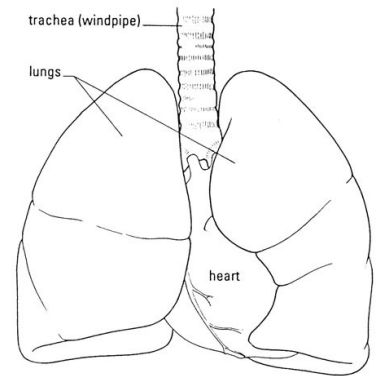


LAB - Dissection of Sheep's Pluck

Purpose: Today we will be exploring the structures of the respiratory system. We will also be examining how our lungs move as we breathe. Lastly, we will be describing how the structure of the lungs relate to how we breathe.

Procedure:

1. When handling the sheep's pluck, make sure to wear disposable gloves. Aprons and goggles are also available for additional protection.
2. Examine your specimen. Describe the color, shape, size, and feel of the specimen.
3. What organs/body parts are included in your specimen?
4. Identify the trachea. Is the trachea stiff or flexible? What allows the trachea to stay open and bend? Why is this important?
5. Try to inflate the lungs and observe how they respond. Do not breathe directly into the trachea to do this! Insert a length of rubber tubing into the trachea and attach it to a bellows or foot pump to inflate the lungs and then watch them deflate. It is best not to breathe through the tube into the lungs yourself because of the elastic recoil of the lung tissue: you might inhale a blast of rather unpleasant air!
 - a. What happened to the lungs when air was forced into them?
 - b. Do you think there is a limit to how much air can be pumped into the lungs? Explain your answer
5. Start of cut down the trachea with your dissecting scissors. Does the trachea stay as one tube or does it split as it enters the lung?



6. If the larynx is still attached to your lungs, try forcing air through the larynx while you squeeze it tight. As air moves past the skin and cords in the larynx it may make a noise.

Discuss how similar this is to the noise the animal makes in life.

7. Cut a small piece of spongy lung tissue to examine more closely.

- Are the lungs hollow bags or spongy? _____
- What does the lung tissue look like where you cut into it? _____
- Drop the piece of lung into a beaker of water. Does the piece sink or float? _____
- What does the answer to part c indicate? _____

8. Now let's examine the heart as review. Use a scalpel to remove a portion of this layer and expose the *myocardium* beneath.

- Note the abundance of fat along the paths of various blood vessels. This adipose tissue occurs in the loose connective tissue that underlies the visceral pericardium.
- Identify the following: ***Right Atrium, Right Ventricle, Pulmonary Artery, Left Atrium, Left Ventricle, and the Aorta***

9. Examine the dorsal surface of the heart (the side closest to your back).

- Locate the stumps of two relatively thin-walled blood vessels that enter the right atrium.
- Demonstrate this connection by passing a slender probe through them.
- The upper vessel is the *superior vena cava*, and the lower one is the *inferior vena cava*.

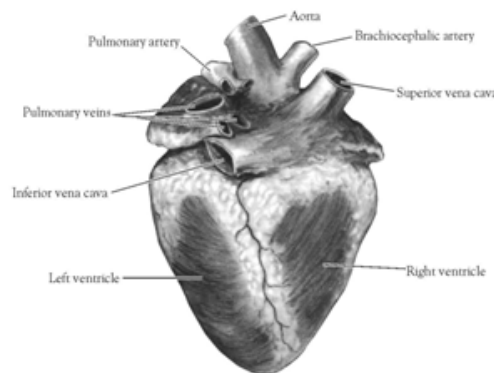


Figure 2. Heart (Posterior View)

10. Open the *right atrium*. To do this, follow these steps:

- Insert a blade of the scissors into the *superior vena cava* and cut downward through the atrial wall.
- Open the chamber, locate the *tricuspid valve* and examine its cusps.
- Run some water through the tricuspid valve to fill the chamber of the *right ventricle*.
- Gently squeeze the ventricles and watch the cusps of the valve as the water moves up against them.

11. Open the *right ventricle* as follows:

- a. Continue cutting downward through the *tricuspid valve* and the *right ventricular wall* until you reach the apex of the heart.
- b. Find the opening to the *pulmonary trunk* and use the scissors to cut upward through the wall of the *right ventricle*. Follow the pulmonary trunk until you have exposed the *pulmonary valve*.
- c. Examine the valve and its cusps.

12. Open the left side of the heart. To do this, follow these steps:

- a. Insert the blade of the scissors through the wall of the *left atrium* and cut downward to the apex of the heart.
- b. Open the *left atrium* and locate the four openings of the *pulmonary veins*. Pass a slender probe through each opening and locate the stump of its vessel.
- c. Examine the *bicuspid valve* (mitral valve) and its cusps.
- d. Also examine the *left ventricle* and compare the thickness of its wall with that of the *right ventricle*.

13. Locate the *aorta*, which leads away from the *left ventricle*, and proceed as follows:

- a. Compare the thickness of the *aortic wall* with that of the *pulmonary trunk*.
- b. Use scissors to cut along the length of the *aorta* to expose the *aortic valve* at its base.
- c. Examine the cusps of the valve and locate the openings of the *coronary arteries* just distal to them.

Questions

1. How many chambers are found in the mammalian heart? List these chambers.
2. Which chambers are the pumping chambers of the heart?
3. Which chambers are the receiving chambers of the heart?

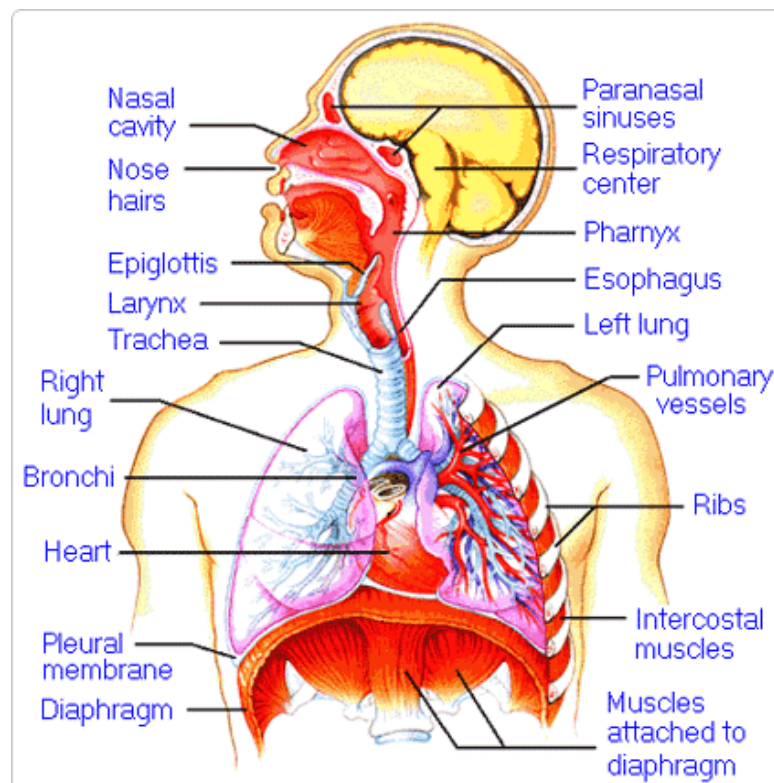
4. How do the walls of the atria compare with the walls of the ventricles and why are they different?

5. What is the purpose of heart valves?

6. Vessels that carry blood away from the heart are called _____, while _____ carry blood toward the heart.

7. Which artery is the largest and why?

8. How are the heart and lungs' function(s) related?

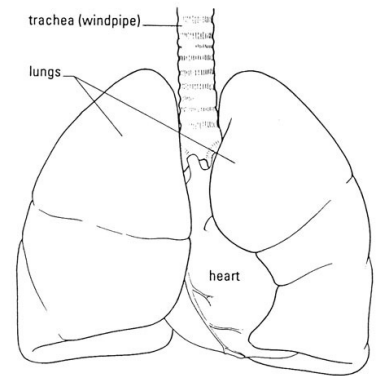


LAB - Dissection of Sheep's Pluck

Purpose: Today we will be exploring the structures of the respiratory system. We will also be examining how our lungs move as we breathe. Lastly, we will be describing how the structure of the lungs relate to how we breathe.

Procedure:

1. When handling the sheep's pluck, make sure to wear disposable gloves. Aprons and goggles are also available for additional protection.
2. Examine your specimen. Describe the color, shape, size, and feel of the specimen.
3. What organs/body parts are included in your specimen?
4. Identify the trachea. Is the trachea stiff or flexible? What allows the trachea to stay open and bend? Why is this important?
5. Try to inflate the lungs and observe how they respond. Do not breathe directly into the trachea to do this! Insert a length of rubber tubing into the trachea and attach it to a bellows or foot pump to inflate the lungs and then watch them deflate. It is best not to breathe through the tube into the lungs yourself because of the elastic recoil of the lung tissue: you might inhale a blast of rather unpleasant air!
 - a. What happened to the lungs when air was forced into them?
 - b. Do you think there is a limit to how much air can be pumped into the lungs? Explain your answer
5. Start of cut down the trachea with your dissecting scissors. Does the trachea stay as one tube or does it split as it enters the lung?



6. If the larynx is still attached to your lungs, try forcing air through the larynx while you squeeze it tight. As air moves past the skin and cords in the larynx it may make a noise.

Discuss how similar this is to the noise the animal makes in life.

7. Cut a small piece of spongy lung tissue to examine more closely.

- Are the lungs hollow bags or spongy? _____
- What does the lung tissue look like where you cut into it? _____
- Drop the piece of lung into a beaker of water. Does the piece sink or float? _____
- What does the answer to part c indicate? _____

8. Now let's examine the heart as review. Use a scalpel to remove a portion of this layer and expose the *myocardium* beneath.

- Note the abundance of fat along the paths of various blood vessels. This adipose tissue occurs in the loose connective tissue that underlies the visceral pericardium.
- Identify the following: ***Right Atrium, Right Ventricle, Pulmonary Artery, Left Atrium, Left Ventricle, and the Aorta***

9. Examine the dorsal surface of the heart (the side closest to your back).

- Locate the stumps of two relatively thin-walled blood vessels that enter the right atrium.
- Demonstrate this connection by passing a slender probe through them.
- The upper vessel is the *superior vena cava*, and the lower one is the *inferior vena cava*.

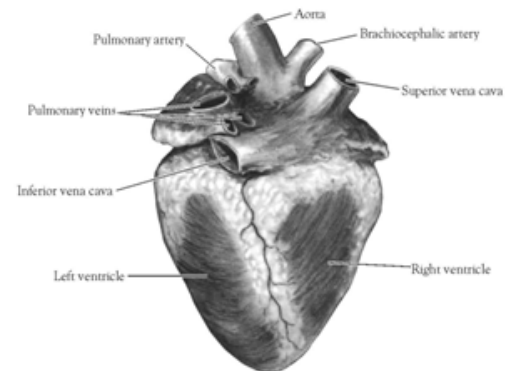


Figure 2. Heart (Posterior View)

10. Open the *right atrium*. To do this, follow these steps:

- Insert a blade of the scissors into the *superior vena cava* and cut downward through the atrial wall.
- Open the chamber, locate the *tricuspid valve* and examine its cusps.
- Run some water through the tricuspid valve to fill the chamber of the *right ventricle*.
- Gently squeeze the ventricles and watch the cusps of the valve as the water moves up against them.

11. Open the *right ventricle* as follows:

- a. Continue cutting downward through the *tricuspid valve* and the *right ventricular wall* until you reach the apex of the heart.
- b. Find the opening to the *pulmonary trunk* and use the scissors to cut upward through the wall of the *right ventricle*. Follow the pulmonary trunk until you have exposed the *pulmonary valve*.
- c. Examine the valve and its cusps.

12. Open the left side of the heart. To do this, follow these steps:

- a. Insert the blade of the scissors through the wall of the *left atrium* and cut downward to the apex of the heart.
- b. Open the *left atrium* and locate the four openings of the *pulmonary veins*. Pass a slender probe through each opening and locate the stump of its vessel.
- c. Examine the *bicuspid valve* (mitral valve) and its cusps.
- d. Also examine the *left ventricle* and compare the thickness of its wall with that of the *right ventricle*.

13. Locate the *aorta*, which leads away from the *left ventricle*, and proceed as follows:

- a. Compare the thickness of the *aortic wall* with that of the *pulmonary trunk*.
- b. Use scissors to cut along the length of the *aorta* to expose the *aortic valve* at its base.
- c. Examine the cusps of the valve and locate the openings of the *coronary arteries* just distal to them.

Questions

1. How many chambers are found in the mammalian heart? List these chambers.
2. Which chambers are the pumping chambers of the heart?
3. Which chambers are the receiving chambers of the heart?

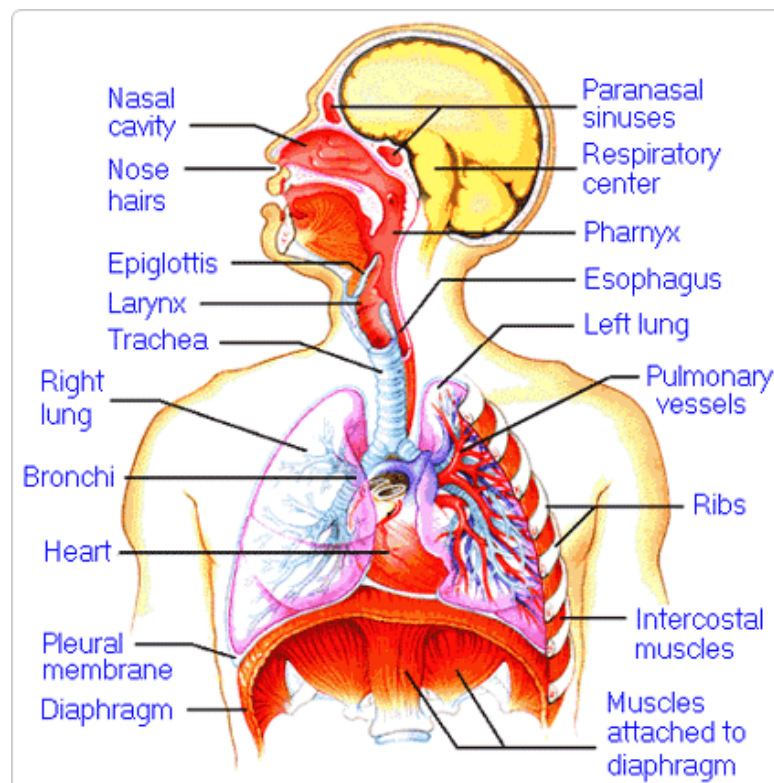
4. How do the walls of the atria compare with the walls of the ventricles and why are they different?

5. What is the purpose of heart valves?

6. Vessels that carry blood away from the heart are called _____, while _____ carry blood toward the heart.

7. Which artery is the largest and why?

8. How are the heart and lungs' function(s) related?

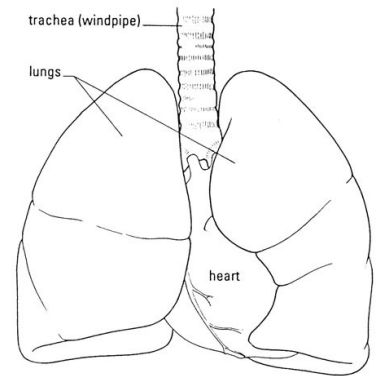


LAB - Dissection of Sheep's Pluck

Purpose: Today we will be exploring the structures of the respiratory system. We will also be examining how our lungs move as we breathe. Lastly, we will be describing how the structure of the lungs relate to how we breathe.

Procedure:

1. When handling the sheep's pluck, make sure to wear disposable gloves. Aprons and goggles are also available for additional protection.
2. Examine your specimen. Describe the color, shape, size, and feel of the specimen.
3. What organs/body parts are included in your specimen?
4. Identify the trachea. Is the trachea stiff or flexible? What allows the trachea to stay open and bend? Why is this important?
5. Try to inflate the lungs and observe how they respond. Do not breathe directly into the trachea to do this! Insert a length of rubber tubing into the trachea and attach it to a bellows or foot pump to inflate the lungs and then watch them deflate. It is best not to breathe through the tube into the lungs yourself because of the elastic recoil of the lung tissue: you might inhale a blast of rather unpleasant air!
 - a. What happened to the lungs when air was forced into them?
 - b. Do you think there is a limit to how much air can be pumped into the lungs? Explain your answer
5. Start of cut down the trachea with your dissecting scissors. Does the trachea stay as one tube or does it split as it enters the lung?



6. If the larynx is still attached to your lungs, try forcing air through the larynx while you squeeze it tight. As air moves past the skin and cords in the larynx it may make a noise.

Discuss how similar this is to the noise the animal makes in life.

7. Cut a small piece of spongy lung tissue to examine more closely.

- Are the lungs hollow bags or spongy? _____
- What does the lung tissue look like where you cut into it? _____
- Drop the piece of lung into a beaker of water. Does the piece sink or float? _____
- What does the answer to part c indicate? _____

8. Now let's examine the heart as review. Use a scalpel to remove a portion of this layer and expose the *myocardium* beneath.

- Note the abundance of fat along the paths of various blood vessels. This adipose tissue occurs in the loose connective tissue that underlies the visceral pericardium.
- Identify the following: ***Right Atrium, Right Ventricle, Pulmonary Artery, Left Atrium, Left Ventricle, and the Aorta***

9. Examine the dorsal surface of the heart (the side closest to your back).

- Locate the stumps of two relatively thin-walled blood vessels that enter the right atrium.
- Demonstrate this connection by passing a slender probe through them.
- The upper vessel is the *superior vena cava*, and the lower one is the *inferior vena cava*.

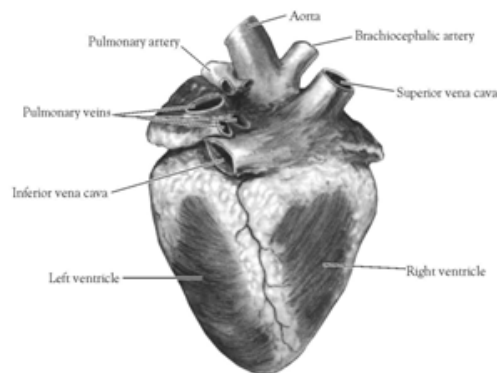


Figure 2. Heart (Posterior View)

10. Open the *right atrium*. To do this, follow these steps:

- Insert a blade of the scissors into the *superior vena cava* and cut downward through the atrial wall.
- Open the chamber, locate the *tricuspid valve* and examine its cusps.
- Run some water through the tricuspid valve to fill the chamber of the *right ventricle*.
- Gently squeeze the ventricles and watch the cusps of the valve as the water moves up against them.

11. Open the *right ventricle* as follows:

- a. Continue cutting downward through the *tricuspid valve* and the *right ventricular wall* until you reach the apex of the heart.
- b. Find the opening to the *pulmonary trunk* and use the scissors to cut upward through the wall of the *right ventricle*. Follow the pulmonary trunk until you have exposed the *pulmonary valve*.
- c. Examine the valve and its cusps.

12. Open the left side of the heart. To do this, follow these steps:

- a. Insert the blade of the scissors through the wall of the *left atrium* and cut downward to the apex of the heart.
- b. Open the *left atrium* and locate the four openings of the *pulmonary veins*. Pass a slender probe through each opening and locate the stump of its vessel.
- c. Examine the *bicuspid valve* (mitral valve) and its cusps.
- d. Also examine the *left ventricle* and compare the thickness of its wall with that of the *right ventricle*.

13. Locate the *aorta*, which leads away from the *left ventricle*, and proceed as follows:

- a. Compare the thickness of the *aortic wall* with that of the *pulmonary trunk*.
- b. Use scissors to cut along the length of the *aorta* to expose the *aortic valve* at its base.
- c. Examine the cusps of the valve and locate the openings of the *coronary arteries* just distal to them.

Questions

1. How many chambers are found in the mammalian heart? List these chambers.
2. Which chambers are the pumping chambers of the heart?
3. Which chambers are the receiving chambers of the heart?

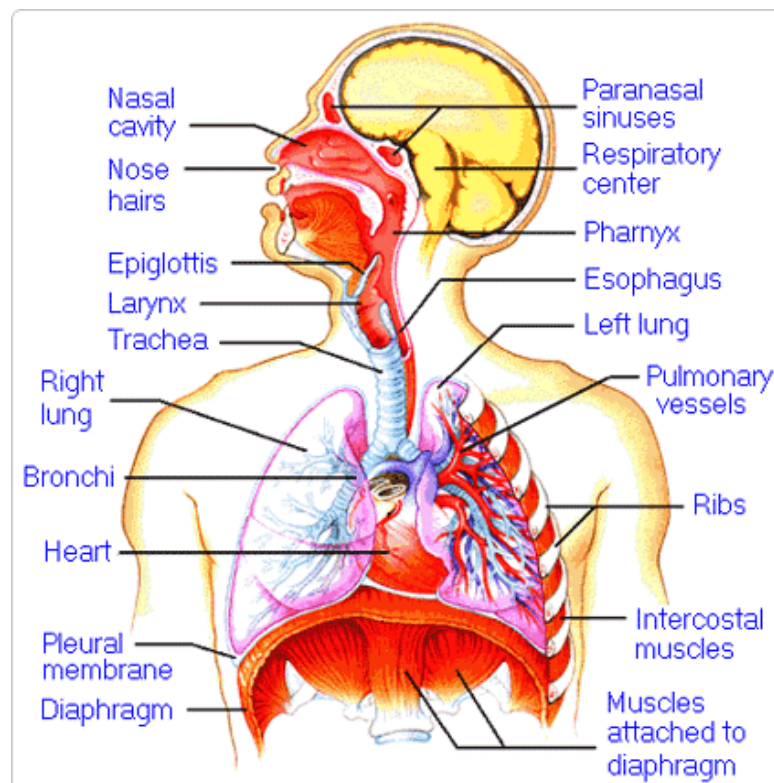
4. How do the walls of the atria compare with the walls of the ventricles and why are they different?

5. What is the purpose of heart valves?

6. Vessels that carry blood away from the heart are called _____, while _____ carry blood toward the heart.

7. Which artery is the largest and why?

8. How are the heart and lungs' function(s) related?

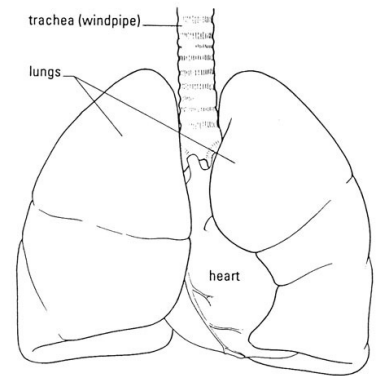


LAB - Dissection of Sheep's Pluck

Purpose: Today we will be exploring the structures of the respiratory system. We will also be examining how our lungs move as we breathe. Lastly, we will be describing how the structure of the lungs relate to how we breathe.

Procedure:

1. When handling the sheep's pluck, make sure to wear disposable gloves. Aprons and goggles are also available for additional protection.
2. Examine your specimen. Describe the color, shape, size, and feel of the specimen.
3. What organs/body parts are included in your specimen?
4. Identify the trachea. Is the trachea stiff or flexible? What allows the trachea to stay open and bend? Why is this important?
5. Try to inflate the lungs and observe how they respond. Do not breathe directly into the trachea to do this! Insert a length of rubber tubing into the trachea and attach it to a bellows or foot pump to inflate the lungs and then watch them deflate. It is best not to breathe through the tube into the lungs yourself because of the elastic recoil of the lung tissue: you might inhale a blast of rather unpleasant air!
 - a. What happened to the lungs when air was forced into them?
 - b. Do you think there is a limit to how much air can be pumped into the lungs? Explain your answer
5. Start of cut down the trachea with your dissecting scissors. Does the trachea stay as one tube or does it split as it enters the lung?



6. If the larynx is still attached to your lungs, try forcing air through the larynx while you squeeze it tight. As air moves past the skin and cords in the larynx it may make a noise.

Discuss how similar this is to the noise the animal makes in life.

7. Cut a small piece of spongy lung tissue to examine more closely.

- Are the lungs hollow bags or spongy? _____
- What does the lung tissue look like where you cut into it? _____
- Drop the piece of lung into a beaker of water. Does the piece sink or float? _____
- What does the answer to part c indicate? _____

8. Now let's examine the heart as review. Use a scalpel to remove a portion of this layer and expose the *myocardium* beneath.

- Note the abundance of fat along the paths of various blood vessels. This adipose tissue occurs in the loose connective tissue that underlies the visceral pericardium.
- Identify the following: ***Right Atrium, Right Ventricle, Pulmonary Artery, Left Atrium, Left Ventricle, and the Aorta***

9. Examine the dorsal surface of the heart (the side closest to your back).

- Locate the stumps of two relatively thin-walled blood vessels that enter the right atrium.
- Demonstrate this connection by passing a slender probe through them.
- The upper vessel is the *superior vena cava*, and the lower one is the *inferior vena cava*.

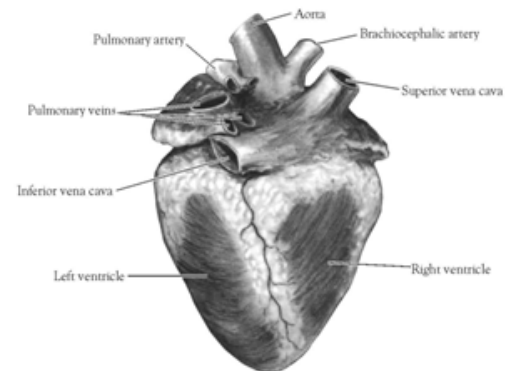


Figure 2. Heart (Posterior View)

10. Open the *right atrium*. To do this, follow these steps:

- Insert a blade of the scissors into the *superior vena cava* and cut downward through the atrial wall.
- Open the chamber, locate the *tricuspid valve* and examine its cusps.
- Run some water through the tricuspid valve to fill the chamber of the *right ventricle*.
- Gently squeeze the ventricles and watch the cusps of the valve as the water moves up against them.

11. Open the *right ventricle* as follows:

- a. Continue cutting downward through the *tricuspid valve* and the *right ventricular wall* until you reach the apex of the heart.
- b. Find the opening to the *pulmonary trunk* and use the scissors to cut upward through the wall of the *right ventricle*. Follow the pulmonary trunk until you have exposed the *pulmonary valve*.
- c. Examine the valve and its cusps.

12. Open the left side of the heart. To do this, follow these steps:

- a. Insert the blade of the scissors through the wall of the *left atrium* and cut downward to the apex of the heart.
- b. Open the *left atrium* and locate the four openings of the *pulmonary veins*. Pass a slender probe through each opening and locate the stump of its vessel.
- c. Examine the *bicuspid valve* (mitral valve) and its cusps.
- d. Also examine the *left ventricle* and compare the thickness of its wall with that of the *right ventricle*.

13. Locate the *aorta*, which leads away from the *left ventricle*, and proceed as follows:

- a. Compare the thickness of the *aortic wall* with that of the *pulmonary trunk*.
- b. Use scissors to cut along the length of the *aorta* to expose the *aortic valve* at its base.
- c. Examine the cusps of the valve and locate the openings of the *coronary arteries* just distal to them.

Questions

1. How many chambers are found in the mammalian heart? List these chambers.
2. Which chambers are the pumping chambers of the heart?
3. Which chambers are the receiving chambers of the heart?

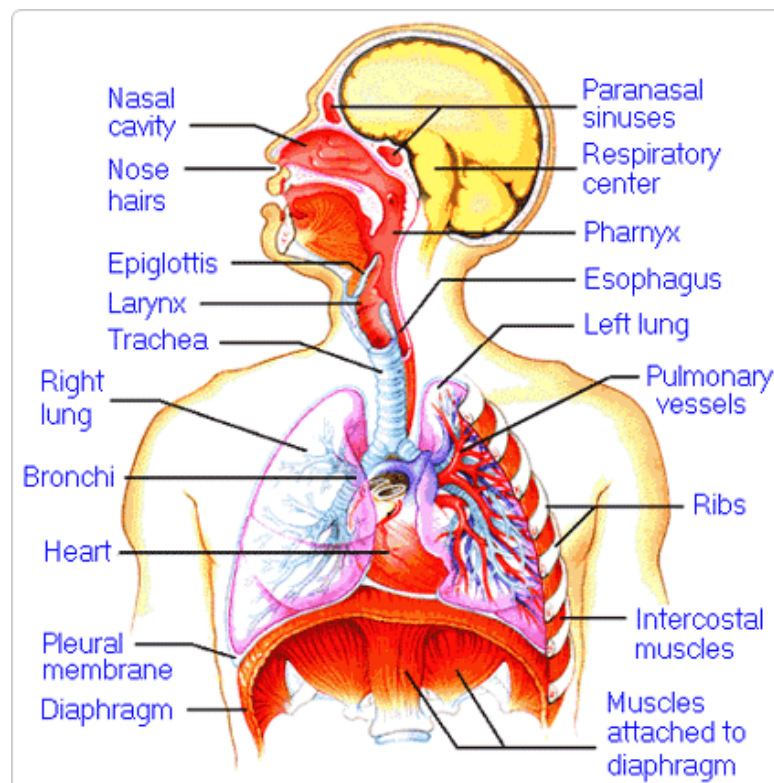
4. How do the walls of the atria compare with the walls of the ventricles and why are they different?

5. What is the purpose of heart valves?

6. Vessels that carry blood away from the heart are called _____, while _____ carry blood toward the heart.

7. Which artery is the largest and why?

8. How are the heart and lungs' function(s) related?

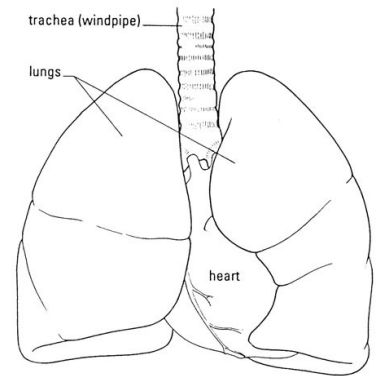


LAB - Dissection of Sheep's Pluck

Purpose: Today we will be exploring the structures of the respiratory system. We will also be examining how our lungs move as we breathe. Lastly, we will be describing how the structure of the lungs relate to how we breathe.

Procedure:

1. When handling the sheep's pluck, make sure to wear disposable gloves. Aprons and goggles are also available for additional protection.
2. Examine your specimen. Describe the color, shape, size, and feel of the specimen.
3. What organs/body parts are included in your specimen?
4. Identify the trachea. Is the trachea stiff or flexible? What allows the trachea to stay open and bend? Why is this important?
5. Try to inflate the lungs and observe how they respond. Do not breathe directly into the trachea to do this! Insert a length of rubber tubing into the trachea and attach it to a bellows or foot pump to inflate the lungs and then watch them deflate. It is best not to breathe through the tube into the lungs yourself because of the elastic recoil of the lung tissue: you might inhale a blast of rather unpleasant air!
 - a. What happened to the lungs when air was forced into them?
 - b. Do you think there is a limit to how much air can be pumped into the lungs? Explain your answer
5. Start of cut down the trachea with your dissecting scissors. Does the trachea stay as one tube or does it split as it enters the lung?



6. If the larynx is still attached to your lungs, try forcing air through the larynx while you squeeze it tight. As air moves past the skin and cords in the larynx it may make a noise.

Discuss how similar this is to the noise the animal makes in life.

7. Cut a small piece of spongy lung tissue to examine more closely.

- Are the lungs hollow bags or spongy? _____
- What does the lung tissue look like where you cut into it? _____
- Drop the piece of lung into a beaker of water. Does the piece sink or float? _____
- What does the answer to part c indicate? _____

8. Now let's examine the heart as review. Use a scalpel to remove a portion of this layer and expose the *myocardium* beneath.

- Note the abundance of fat along the paths of various blood vessels. This adipose tissue occurs in the loose connective tissue that underlies the visceral pericardium.
- Identify the following: ***Right Atrium, Right Ventricle, Pulmonary Artery, Left Atrium, Left Ventricle, and the Aorta***

9. Examine the dorsal surface of the heart (the side closest to your back).

- Locate the stumps of two relatively thin-walled blood vessels that enter the right atrium.
- Demonstrate this connection by passing a slender probe through them.
- The upper vessel is the *superior vena cava*, and the lower one is the *inferior vena cava*.

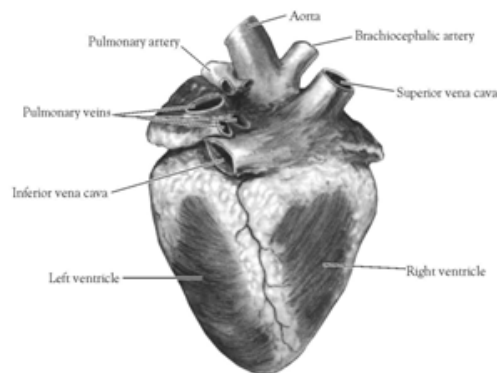


Figure 2. Heart (Posterior View)

10. Open the *right atrium*. To do this, follow these steps:

- Insert a blade of the scissors into the *superior vena cava* and cut downward through the atrial wall.
- Open the chamber, locate the *tricuspid valve* and examine its cusps.
- Run some water through the tricuspid valve to fill the chamber of the *right ventricle*.
- Gently squeeze the ventricles and watch the cusps of the valve as the water moves up against them.

11. Open the *right ventricle* as follows:

- a. Continue cutting downward through the *tricuspid valve* and the *right ventricular wall* until you reach the apex of the heart.
- b. Find the opening to the *pulmonary trunk* and use the scissors to cut upward through the wall of the *right ventricle*. Follow the pulmonary trunk until you have exposed the *pulmonary valve*.
- c. Examine the valve and its cusps.

12. Open the left side of the heart. To do this, follow these steps:

- a. Insert the blade of the scissors through the wall of the *left atrium* and cut downward to the apex of the heart.
- b. Open the *left atrium* and locate the four openings of the *pulmonary veins*. Pass a slender probe through each opening and locate the stump of its vessel.
- c. Examine the *bicuspid valve* (mitral valve) and its cusps.
- d. Also examine the *left ventricle* and compare the thickness of its wall with that of the *right ventricle*.

13. Locate the *aorta*, which leads away from the *left ventricle*, and proceed as follows:

- a. Compare the thickness of the *aortic wall* with that of the *pulmonary trunk*.
- b. Use scissors to cut along the length of the *aorta* to expose the *aortic valve* at its base.
- c. Examine the cusps of the valve and locate the openings of the *coronary arteries* just distal to them.

Questions

1. How many chambers are found in the mammalian heart? List these chambers.
2. Which chambers are the pumping chambers of the heart?
3. Which chambers are the receiving chambers of the heart?

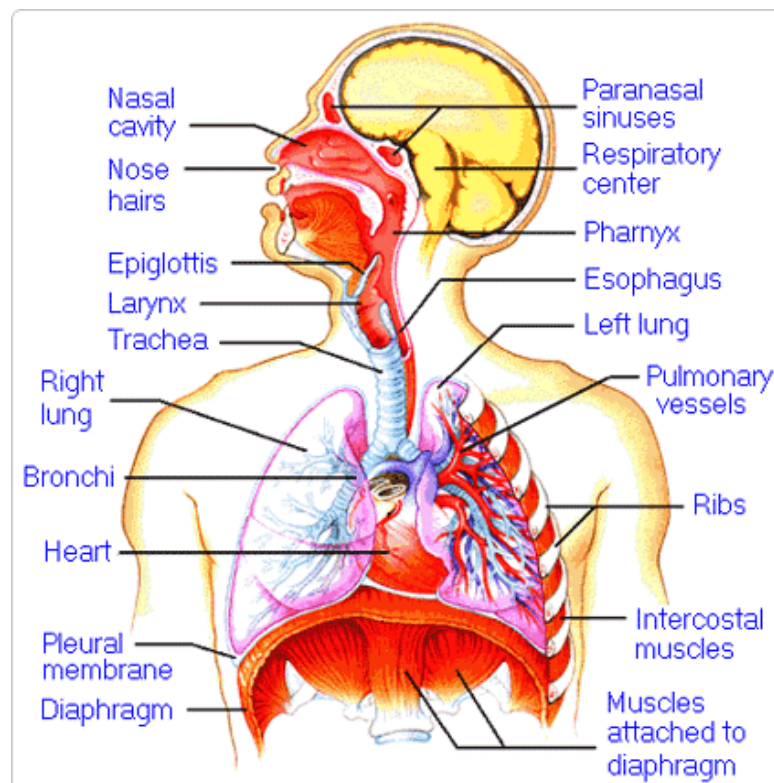
4. How do the walls of the atria compare with the walls of the ventricles and why are they different?

5. What is the purpose of heart valves?

6. Vessels that carry blood away from the heart are called _____, while _____ carry blood toward the heart.

7. Which artery is the largest and why?

8. How are the heart and lungs' function(s) related?

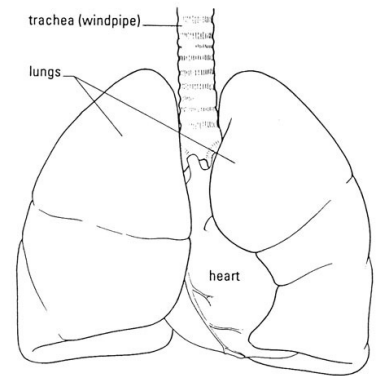


LAB - Dissection of Sheep's Pluck

Purpose: Today we will be exploring the structures of the respiratory system. We will also be examining how our lungs move as we breathe. Lastly, we will be describing how the structure of the lungs relate to how we breathe.

Procedure:

1. When handling the sheep's pluck, make sure to wear disposable gloves. Aprons and goggles are also available for additional protection.
2. Examine your specimen. Describe the color, shape, size, and feel of the specimen.
3. What organs/body parts are included in your specimen?
4. Identify the trachea. Is the trachea stiff or flexible? What allows the trachea to stay open and bend? Why is this important?
5. Try to inflate the lungs and observe how they respond. Do not breathe directly into the trachea to do this! Insert a length of rubber tubing into the trachea and attach it to a bellows or foot pump to inflate the lungs and then watch them deflate. It is best not to breathe through the tube into the lungs yourself because of the elastic recoil of the lung tissue: you might inhale a blast of rather unpleasant air!
 - a. What happened to the lungs when air was forced into them?
 - b. Do you think there is a limit to how much air can be pumped into the lungs? Explain your answer
5. Start of cut down the trachea with your dissecting scissors. Does the trachea stay as one tube or does it split as it enters the lung?



6. If the larynx is still attached to your lungs, try forcing air through the larynx while you squeeze it tight. As air moves past the skin and cords in the larynx it may make a noise.

Discuss how similar this is to the noise the animal makes in life.

7. Cut a small piece of spongy lung tissue to examine more closely.

- Are the lungs hollow bags or spongy? _____
- What does the lung tissue look like where you cut into it? _____
- Drop the piece of lung into a beaker of water. Does the piece sink or float? _____
- What does the answer to part c indicate? _____

8. Now let's examine the heart as review. Use a scalpel to remove a portion of this layer and expose the *myocardium* beneath.

- Note the abundance of fat along the paths of various blood vessels. This adipose tissue occurs in the loose connective tissue that underlies the visceral pericardium.
- Identify the following: ***Right Atrium, Right Ventricle, Pulmonary Artery, Left Atrium, Left Ventricle, and the Aorta***

9. Examine the dorsal surface of the heart (the side closest to your back).

- Locate the stumps of two relatively thin-walled blood vessels that enter the right atrium.
- Demonstrate this connection by passing a slender probe through them.
- The upper vessel is the *superior vena cava*, and the lower one is the *inferior vena cava*.

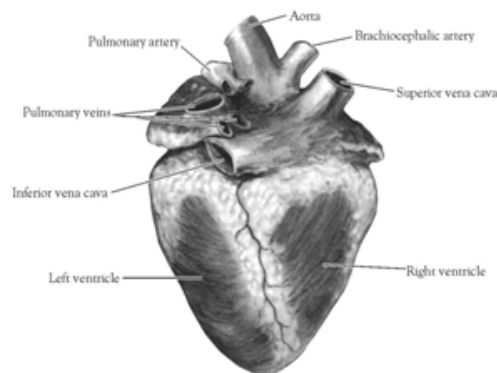


Figure 2. Heart (Posterior View)

10. Open the *right atrium*. To do this, follow these steps:

- Insert a blade of the scissors into the *superior vena cava* and cut downward through the atrial wall.
- Open the chamber, locate the *tricuspid valve* and examine its cusps.
- Run some water through the tricuspid valve to fill the chamber of the *right ventricle*.
- Gently squeeze the ventricles and watch the cusps of the valve as the water moves up against them.

11. Open the *right ventricle* as follows:

- a. Continue cutting downward through the *tricuspid valve* and the *right ventricular wall* until you reach the apex of the heart.
- b. Find the opening to the *pulmonary trunk* and use the scissors to cut upward through the wall of the *right ventricle*. Follow the pulmonary trunk until you have exposed the *pulmonary valve*.
- c. Examine the valve and its cusps.

12. Open the left side of the heart. To do this, follow these steps:

- a. Insert the blade of the scissors through the wall of the *left atrium* and cut downward to the apex of the heart.
- b. Open the *left atrium* and locate the four openings of the *pulmonary veins*. Pass a slender probe through each opening and locate the stump of its vessel.
- c. Examine the *bicuspid valve* (mitral valve) and its cusps.
- d. Also examine the *left ventricle* and compare the thickness of its wall with that of the *right ventricle*.

13. Locate the *aorta*, which leads away from the *left ventricle*, and proceed as follows:

- a. Compare the thickness of the *aortic wall* with that of the *pulmonary trunk*.
- b. Use scissors to cut along the length of the *aorta* to expose the *aortic valve* at its base.
- c. Examine the cusps of the valve and locate the openings of the *coronary arteries* just distal to them.

Questions

1. How many chambers are found in the mammalian heart? List these chambers.
2. Which chambers are the pumping chambers of the heart?
3. Which chambers are the receiving chambers of the heart?

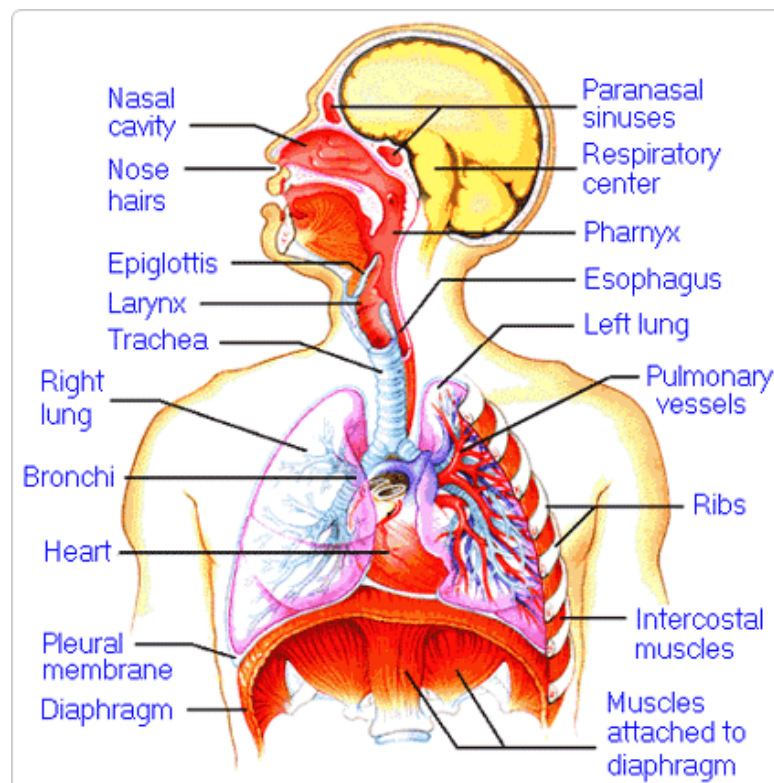
4. How do the walls of the atria compare with the walls of the ventricles and why are they different?

5. What is the purpose of heart valves?

6. Vessels that carry blood away from the heart are called _____, while _____ carry blood toward the heart.

7. Which artery is the largest and why?

8. How are the heart and lungs' function(s) related?

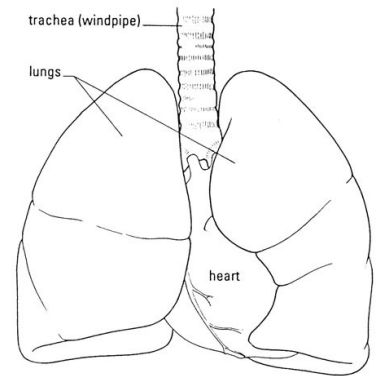


LAB - Dissection of Sheep's Pluck

Purpose: Today we will be exploring the structures of the respiratory system. We will also be examining how our lungs move as we breathe. Lastly, we will be describing how the structure of the lungs relate to how we breathe.

Procedure:

1. When handling the sheep's pluck, make sure to wear disposable gloves. Aprons and goggles are also available for additional protection.
2. Examine your specimen. Describe the color, shape, size, and feel of the specimen.
3. What organs/body parts are included in your specimen?
4. Identify the trachea. Is the trachea stiff or flexible? What allows the trachea to stay open and bend? Why is this important?
5. Try to inflate the lungs and observe how they respond. Do not breathe directly into the trachea to do this! Insert a length of rubber tubing into the trachea and attach it to a bellows or foot pump to inflate the lungs and then watch them deflate. It is best not to breathe through the tube into the lungs yourself because of the elastic recoil of the lung tissue: you might inhale a blast of rather unpleasant air!
 - a. What happened to the lungs when air was forced into them?
 - b. Do you think there is a limit to how much air can be pumped into the lungs? Explain your answer
5. Start of cut down the trachea with your dissecting scissors. Does the trachea stay as one tube or does it split as it enters the lung?



6. If the larynx is still attached to your lungs, try forcing air through the larynx while you squeeze it tight. As air moves past the skin and cords in the larynx it may make a noise.

Discuss how similar this is to the noise the animal makes in life.

7. Cut a small piece of spongy lung tissue to examine more closely.

- Are the lungs hollow bags or spongy? _____
- What does the lung tissue look like where you cut into it? _____
- Drop the piece of lung into a beaker of water. Does the piece sink or float? _____
- What does the answer to part c indicate? _____

8. Now let's examine the heart as review. Use a scalpel to remove a portion of this layer and expose the *myocardium* beneath.

- Note the abundance of fat along the paths of various blood vessels. This adipose tissue occurs in the loose connective tissue that underlies the visceral pericardium.
- Identify the following: ***Right Atrium, Right Ventricle, Pulmonary Artery, Left Atrium, Left Ventricle, and the Aorta***

9. Examine the dorsal surface of the heart (the side closest to your back).

- Locate the stumps of two relatively thin-walled blood vessels that enter the right atrium.
- Demonstrate this connection by passing a slender probe through them.
- The upper vessel is the *superior vena cava*, and the lower one is the *inferior vena cava*.

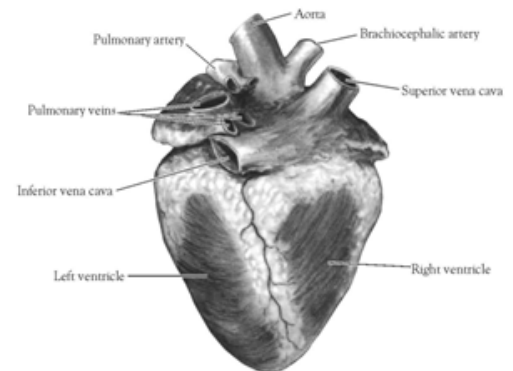


Figure 2. Heart (Posterior View)

10. Open the *right atrium*. To do this, follow these steps:

- Insert a blade of the scissors into the *superior vena cava* and cut downward through the atrial wall.
- Open the chamber, locate the *tricuspid valve* and examine its cusps.
- Run some water through the tricuspid valve to fill the chamber of the *right ventricle*.
- Gently squeeze the ventricles and watch the cusps of the valve as the water moves up against them.

11. Open the *right ventricle* as follows:

- a. Continue cutting downward through the *tricuspid valve* and the *right ventricular wall* until you reach the apex of the heart.
- b. Find the opening to the *pulmonary trunk* and use the scissors to cut upward through the wall of the *right ventricle*. Follow the pulmonary trunk until you have exposed the *pulmonary valve*.
- c. Examine the valve and its cusps.

12. Open the left side of the heart. To do this, follow these steps:

- a. Insert the blade of the scissors through the wall of the *left atrium* and cut downward to the apex of the heart.
- b. Open the *left atrium* and locate the four openings of the *pulmonary veins*. Pass a slender probe through each opening and locate the stump of its vessel.
- c. Examine the *bicuspid valve* (mitral valve) and its cusps.
- d. Also examine the *left ventricle* and compare the thickness of its wall with that of the *right ventricle*.

13. Locate the *aorta*, which leads away from the *left ventricle*, and proceed as follows:

- a. Compare the thickness of the *aortic wall* with that of the *pulmonary trunk*.
- b. Use scissors to cut along the length of the *aorta* to expose the *aortic valve* at its base.
- c. Examine the cusps of the valve and locate the openings of the *coronary arteries* just distal to them.

Questions

1. How many chambers are found in the mammalian heart? List these chambers.
2. Which chambers are the pumping chambers of the heart?
3. Which chambers are the receiving chambers of the heart?

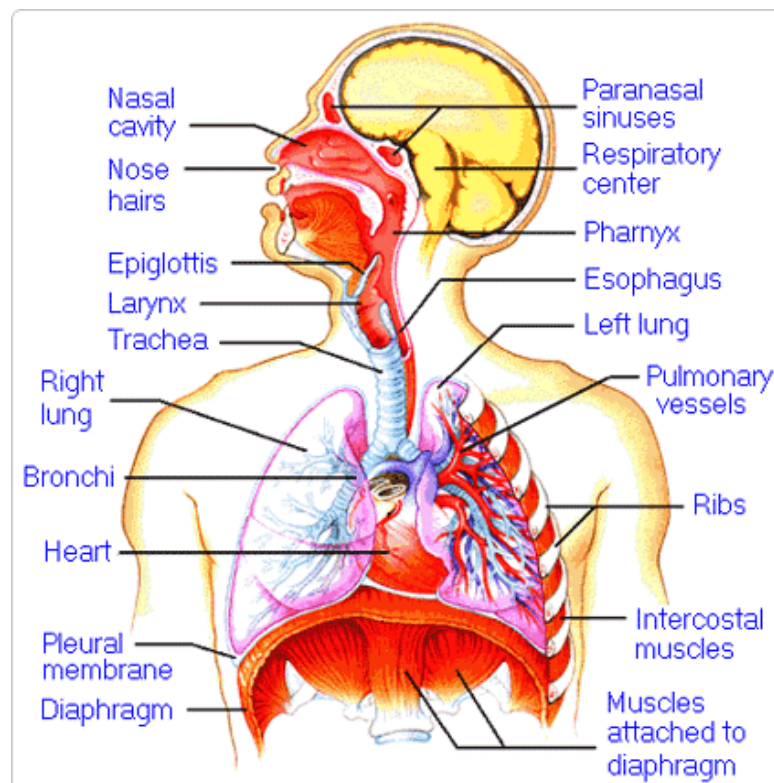
4. How do the walls of the atria compare with the walls of the ventricles and why are they different?

5. What is the purpose of heart valves?

6. Vessels that carry blood away from the heart are called _____, while _____ carry blood toward the heart.

7. Which artery is the largest and why?

8. How are the heart and lungs' function(s) related?

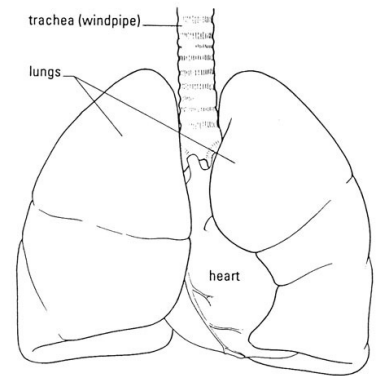


LAB - Dissection of Sheep's Pluck

Purpose: Today we will be exploring the structures of the respiratory system. We will also be examining how our lungs move as we breathe. Lastly, we will be describing how the structure of the lungs relate to how we breathe.

Procedure:

1. When handling the sheep's pluck, make sure to wear disposable gloves. Aprons and goggles are also available for additional protection.
2. Examine your specimen. Describe the color, shape, size, and feel of the specimen.
3. What organs/body parts are included in your specimen?
4. Identify the trachea. Is the trachea stiff or flexible? What allows the trachea to stay open and bend? Why is this important?
5. Try to inflate the lungs and observe how they respond. Do not breathe directly into the trachea to do this! Insert a length of rubber tubing into the trachea and attach it to a bellows or foot pump to inflate the lungs and then watch them deflate. It is best not to breathe through the tube into the lungs yourself because of the elastic recoil of the lung tissue: you might inhale a blast of rather unpleasant air!
 - a. What happened to the lungs when air was forced into them?
 - b. Do you think there is a limit to how much air can be pumped into the lungs? Explain your answer
5. Start of cut down the trachea with your dissecting scissors. Does the trachea stay as one tube or does it split as it enters the lung?



6. If the larynx is still attached to your lungs, try forcing air through the larynx while you squeeze it tight. As air moves past the skin and cords in the larynx it may make a noise.

Discuss how similar this is to the noise the animal makes in life.

7. Cut a small piece of spongy lung tissue to examine more closely.

- Are the lungs hollow bags or spongy? _____
- What does the lung tissue look like where you cut into it? _____
- Drop the piece of lung into a beaker of water. Does the piece sink or float? _____
- What does the answer to part c indicate? _____

8. Now let's examine the heart as review. Use a scalpel to remove a portion of this layer and expose the *myocardium* beneath.

- Note the abundance of fat along the paths of various blood vessels. This adipose tissue occurs in the loose connective tissue that underlies the visceral pericardium.
- Identify the following: ***Right Atrium, Right Ventricle, Pulmonary Artery, Left Atrium, Left Ventricle, and the Aorta***

9. Examine the dorsal surface of the heart (the side closest to your back).

- Locate the stumps of two relatively thin-walled blood vessels that enter the right atrium.
- Demonstrate this connection by passing a slender probe through them.
- The upper vessel is the *superior vena cava*, and the lower one is the *inferior vena cava*.

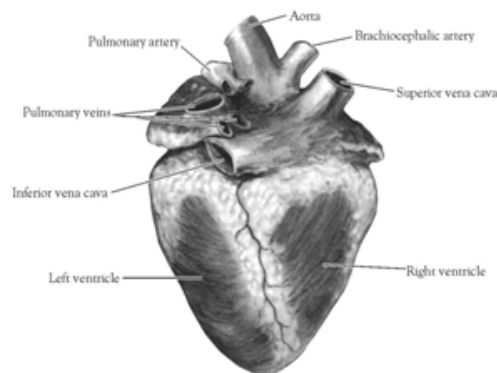


Figure 2. Heart (Posterior View)

10. Open the *right atrium*. To do this, follow these steps:

- Insert a blade of the scissors into the *superior vena cava* and cut downward through the atrial wall.
- Open the chamber, locate the *tricuspid valve* and examine its cusps.
- Run some water through the tricuspid valve to fill the chamber of the *right ventricle*.
- Gently squeeze the ventricles and watch the cusps of the valve as the water moves up against them.

11. Open the *right ventricle* as follows:

- a. Continue cutting downward through the *tricuspid valve* and the *right ventricular wall* until you reach the apex of the heart.
- b. Find the opening to the *pulmonary trunk* and use the scissors to cut upward through the wall of the *right ventricle*. Follow the pulmonary trunk until you have exposed the *pulmonary valve*.
- c. Examine the valve and its cusps.

12. Open the left side of the heart. To do this, follow these steps:

- a. Insert the blade of the scissors through the wall of the *left atrium* and cut downward to the apex of the heart.
- b. Open the *left atrium* and locate the four openings of the *pulmonary veins*. Pass a slender probe through each opening and locate the stump of its vessel.
- c. Examine the *bicuspid valve* (mitral valve) and its cusps.
- d. Also examine the *left ventricle* and compare the thickness of its wall with that of the *right ventricle*.

13. Locate the *aorta*, which leads away from the *left ventricle*, and proceed as follows:

- a. Compare the thickness of the *aortic wall* with that of the *pulmonary trunk*.
- b. Use scissors to cut along the length of the *aorta* to expose the *aortic valve* at its base.
- c. Examine the cusps of the valve and locate the openings of the *coronary arteries* just distal to them.

Questions

1. How many chambers are found in the mammalian heart? List these chambers.
2. Which chambers are the pumping chambers of the heart?
3. Which chambers are the receiving chambers of the heart?

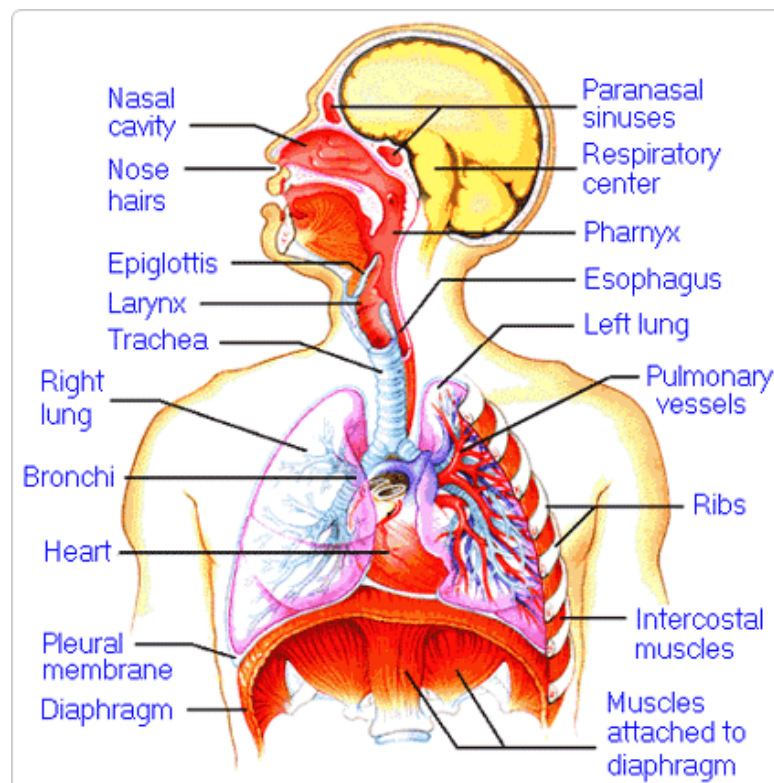
4. How do the walls of the atria compare with the walls of the ventricles and why are they different?

5. What is the purpose of heart valves?

6. Vessels that carry blood away from the heart are called _____, while _____ carry blood toward the heart.

7. Which artery is the largest and why?

8. How are the heart and lungs' function(s) related?

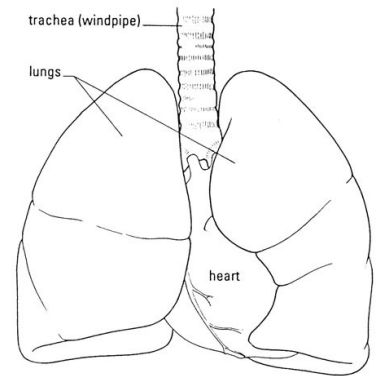


LAB - Dissection of Sheep's Pluck

Purpose: Today we will be exploring the structures of the respiratory system. We will also be examining how our lungs move as we breathe. Lastly, we will be describing how the structure of the lungs relate to how we breathe.

Procedure:

1. When handling the sheep's pluck, make sure to wear disposable gloves. Aprons and goggles are also available for additional protection.
2. Examine your specimen. Describe the color, shape, size, and feel of the specimen.
3. What organs/body parts are included in your specimen?
4. Identify the trachea. Is the trachea stiff or flexible? What allows the trachea to stay open and bend? Why is this important?
5. Try to inflate the lungs and observe how they respond. Do not breathe directly into the trachea to do this! Insert a length of rubber tubing into the trachea and attach it to a bellows or foot pump to inflate the lungs and then watch them deflate. It is best not to breathe through the tube into the lungs yourself because of the elastic recoil of the lung tissue: you might inhale a blast of rather unpleasant air!
 - a. What happened to the lungs when air was forced into them?
 - b. Do you think there is a limit to how much air can be pumped into the lungs? Explain your answer
5. Start of cut down the trachea with your dissecting scissors. Does the trachea stay as one tube or does it split as it enters the lung?



6. If the larynx is still attached to your lungs, try forcing air through the larynx while you squeeze it tight. As air moves past the skin and cords in the larynx it may make a noise.

Discuss how similar this is to the noise the animal makes in life.

7. Cut a small piece of spongy lung tissue to examine more closely.

- Are the lungs hollow bags or spongy? _____
- What does the lung tissue look like where you cut into it? _____
- Drop the piece of lung into a beaker of water. Does the piece sink or float? _____
- What does the answer to part c indicate? _____

8. Now let's examine the heart as review. Use a scalpel to remove a portion of this layer and expose the *myocardium* beneath.

- Note the abundance of fat along the paths of various blood vessels. This adipose tissue occurs in the loose connective tissue that underlies the visceral pericardium.
- Identify the following: ***Right Atrium, Right Ventricle, Pulmonary Artery, Left Atrium, Left Ventricle, and the Aorta***

9. Examine the dorsal surface of the heart (the side closest to your back).

- Locate the stumps of two relatively thin-walled blood vessels that enter the right atrium.
- Demonstrate this connection by passing a slender probe through them.
- The upper vessel is the *superior vena cava*, and the lower one is the *inferior vena cava*.

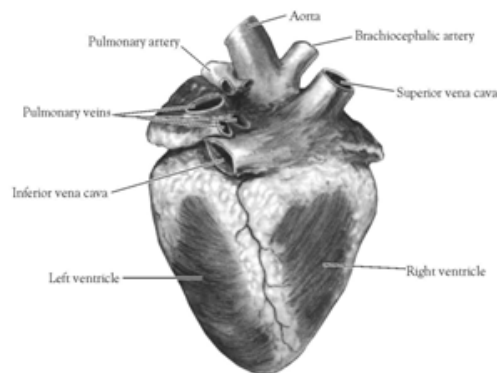


Figure 2. Heart (Posterior View)

10. Open the *right atrium*. To do this, follow these steps:

- Insert a blade of the scissors into the *superior vena cava* and cut downward through the atrial wall.
- Open the chamber, locate the *tricuspid valve* and examine its cusps.
- Run some water through the tricuspid valve to fill the chamber of the *right ventricle*.
- Gently squeeze the ventricles and watch the cusps of the valve as the water moves up against them.

11. Open the *right ventricle* as follows:

- a. Continue cutting downward through the *tricuspid valve* and the *right ventricular wall* until you reach the apex of the heart.
- b. Find the opening to the *pulmonary trunk* and use the scissors to cut upward through the wall of the *right ventricle*. Follow the pulmonary trunk until you have exposed the *pulmonary valve*.
- c. Examine the valve and its cusps.

12. Open the left side of the heart. To do this, follow these steps:

- a. Insert the blade of the scissors through the wall of the *left atrium* and cut downward to the apex of the heart.
- b. Open the *left atrium* and locate the four openings of the *pulmonary veins*. Pass a slender probe through each opening and locate the stump of its vessel.
- c. Examine the *bicuspid valve* (mitral valve) and its cusps.
- d. Also examine the *left ventricle* and compare the thickness of its wall with that of the *right ventricle*.

13. Locate the *aorta*, which leads away from the *left ventricle*, and proceed as follows:

- a. Compare the thickness of the *aortic wall* with that of the *pulmonary trunk*.
- b. Use scissors to cut along the length of the *aorta* to expose the *aortic valve* at its base.
- c. Examine the cusps of the valve and locate the openings of the *coronary arteries* just distal to them.

Questions

1. How many chambers are found in the mammalian heart? List these chambers.
2. Which chambers are the pumping chambers of the heart?
3. Which chambers are the receiving chambers of the heart?

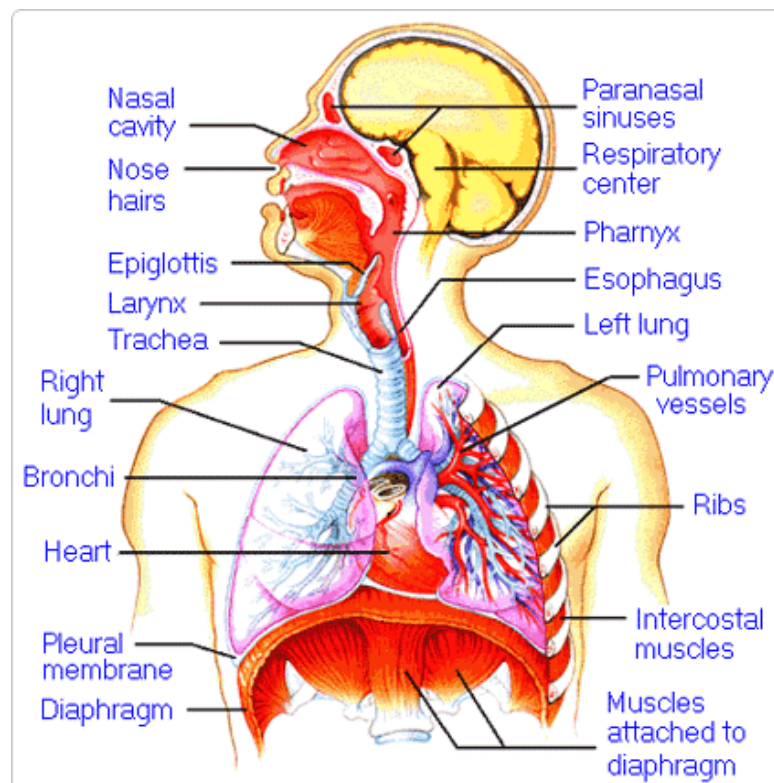
4. How do the walls of the atria compare with the walls of the ventricles and why are they different?

5. What is the purpose of heart valves?

6. Vessels that carry blood away from the heart are called _____, while _____ carry blood toward the heart.

7. Which artery is the largest and why?

8. How are the heart and lungs' function(s) related?

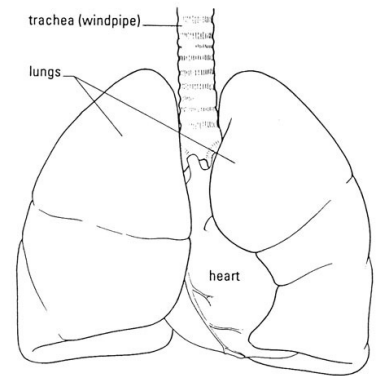


LAB - Dissection of Sheep's Pluck

Purpose: Today we will be exploring the structures of the respiratory system. We will also be examining how our lungs move as we breathe. Lastly, we will be describing how the structure of the lungs relate to how we breathe.

Procedure:

1. When handling the sheep's pluck, make sure to wear disposable gloves. Aprons and goggles are also available for additional protection.
2. Examine your specimen. Describe the color, shape, size, and feel of the specimen.
3. What organs/body parts are included in your specimen?
4. Identify the trachea. Is the trachea stiff or flexible? What allows the trachea to stay open and bend? Why is this important?
5. Try to inflate the lungs and observe how they respond. Do not breathe directly into the trachea to do this! Insert a length of rubber tubing into the trachea and attach it to a bellows or foot pump to inflate the lungs and then watch them deflate. It is best not to breathe through the tube into the lungs yourself because of the elastic recoil of the lung tissue: you might inhale a blast of rather unpleasant air!
 - a. What happened to the lungs when air was forced into them?
 - b. Do you think there is a limit to how much air can be pumped into the lungs? Explain your answer
5. Start of cut down the trachea with your dissecting scissors. Does the trachea stay as one tube or does it split as it enters the lung?



6. If the larynx is still attached to your lungs, try forcing air through the larynx while you squeeze it tight. As air moves past the skin and cords in the larynx it may make a noise.

Discuss how similar this is to the noise the animal makes in life.

7. Cut a small piece of spongy lung tissue to examine more closely.

- Are the lungs hollow bags or spongy? _____
- What does the lung tissue look like where you cut into it? _____
- Drop the piece of lung into a beaker of water. Does the piece sink or float? _____
- What does the answer to part c indicate? _____

8. Now let's examine the heart as review. Use a scalpel to remove a portion of this layer and expose the *myocardium* beneath.

- Note the abundance of fat along the paths of various blood vessels. This adipose tissue occurs in the loose connective tissue that underlies the visceral pericardium.
- Identify the following: ***Right Atrium, Right Ventricle, Pulmonary Artery, Left Atrium, Left Ventricle, and the Aorta***

9. Examine the dorsal surface of the heart (the side closest to your back).

- Locate the stumps of two relatively thin-walled blood vessels that enter the right atrium.
- Demonstrate this connection by passing a slender probe through them.
- The upper vessel is the *superior vena cava*, and the lower one is the *inferior vena cava*.

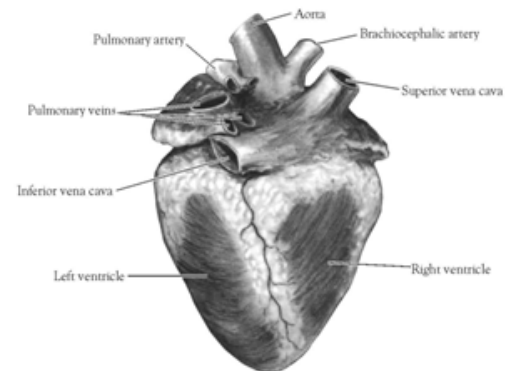


Figure 2. Heart (Posterior View)

10. Open the *right atrium*. To do this, follow these steps:

- Insert a blade of the scissors into the *superior vena cava* and cut downward through the atrial wall.
- Open the chamber, locate the *tricuspid valve* and examine its cusps.
- Run some water through the tricuspid valve to fill the chamber of the *right ventricle*.
- Gently squeeze the ventricles and watch the cusps of the valve as the water moves up against them.

11. Open the *right ventricle* as follows:

- a. Continue cutting downward through the *tricuspid valve* and the *right ventricular wall* until you reach the apex of the heart.
- b. Find the opening to the *pulmonary trunk* and use the scissors to cut upward through the wall of the *right ventricle*. Follow the pulmonary trunk until you have exposed the *pulmonary valve*.
- c. Examine the valve and its cusps.

12. Open the left side of the heart. To do this, follow these steps:

- a. Insert the blade of the scissors through the wall of the *left atrium* and cut downward to the apex of the heart.
- b. Open the *left atrium* and locate the four openings of the *pulmonary veins*. Pass a slender probe through each opening and locate the stump of its vessel.
- c. Examine the *bicuspid valve* (mitral valve) and its cusps.
- d. Also examine the *left ventricle* and compare the thickness of its wall with that of the *right ventricle*.

13. Locate the *aorta*, which leads away from the *left ventricle*, and proceed as follows:

- a. Compare the thickness of the *aortic wall* with that of the *pulmonary trunk*.
- b. Use scissors to cut along the length of the *aorta* to expose the *aortic valve* at its base.
- c. Examine the cusps of the valve and locate the openings of the *coronary arteries* just distal to them.

Questions

1. How many chambers are found in the mammalian heart? List these chambers.
2. Which chambers are the pumping chambers of the heart?
3. Which chambers are the receiving chambers of the heart?

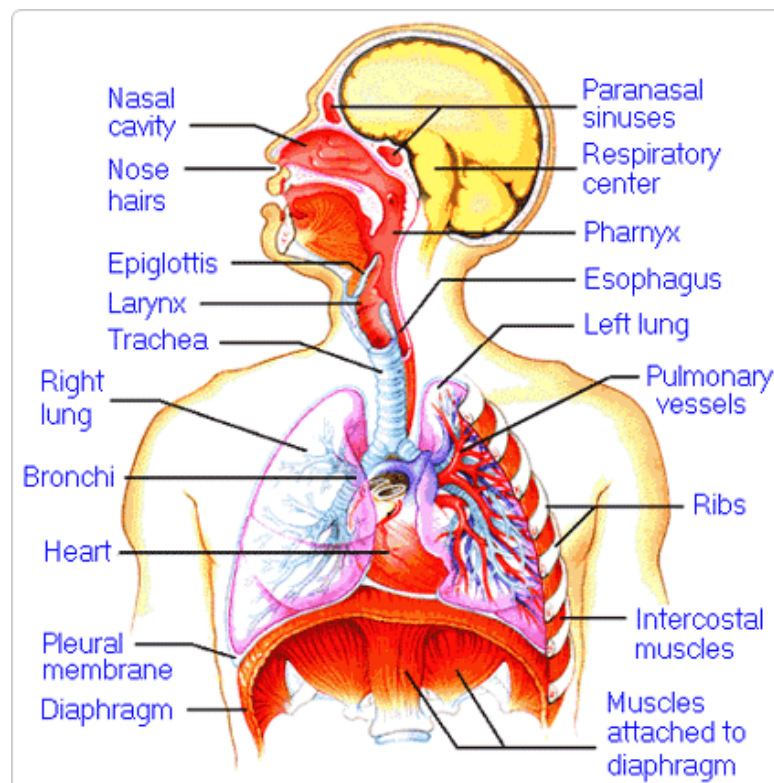
4. How do the walls of the atria compare with the walls of the ventricles and why are they different?

5. What is the purpose of heart valves?

6. Vessels that carry blood away from the heart are called _____, while _____ carry blood toward the heart.

7. Which artery is the largest and why?

8. How are the heart and lungs' function(s) related?

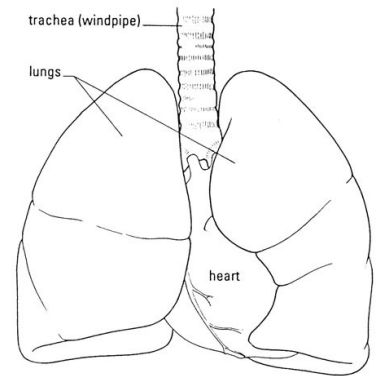


LAB - Dissection of Sheep's Pluck

Purpose: Today we will be exploring the structures of the respiratory system. We will also be examining how our lungs move as we breathe. Lastly, we will be describing how the structure of the lungs relate to how we breathe.

Procedure:

1. When handling the sheep's pluck, make sure to wear disposable gloves. Aprons and goggles are also available for additional protection.
2. Examine your specimen. Describe the color, shape, size, and feel of the specimen.
3. What organs/body parts are included in your specimen?
4. Identify the trachea. Is the trachea stiff or flexible? What allows the trachea to stay open and bend? Why is this important?
5. Try to inflate the lungs and observe how they respond. Do not breathe directly into the trachea to do this! Insert a length of rubber tubing into the trachea and attach it to a bellows or foot pump to inflate the lungs and then watch them deflate. It is best not to breathe through the tube into the lungs yourself because of the elastic recoil of the lung tissue: you might inhale a blast of rather unpleasant air!
 - a. What happened to the lungs when air was forced into them?
 - b. Do you think there is a limit to how much air can be pumped into the lungs? Explain your answer
5. Start of cut down the trachea with your dissecting scissors. Does the trachea stay as one tube or does it split as it enters the lung?



6. If the larynx is still attached to your lungs, try forcing air through the larynx while you squeeze it tight. As air moves past the skin and cords in the larynx it may make a noise.

Discuss how similar this is to the noise the animal makes in life.

7. Cut a small piece of spongy lung tissue to examine more closely.

- Are the lungs hollow bags or spongy? _____
- What does the lung tissue look like where you cut into it? _____
- Drop the piece of lung into a beaker of water. Does the piece sink or float? _____
- What does the answer to part c indicate? _____

8. Now let's examine the heart as review. Use a scalpel to remove a portion of this layer and expose the *myocardium* beneath.

- Note the abundance of fat along the paths of various blood vessels. This adipose tissue occurs in the loose connective tissue that underlies the visceral pericardium.
- Identify the following: ***Right Atrium, Right Ventricle, Pulmonary Artery, Left Atrium, Left Ventricle, and the Aorta***

9. Examine the dorsal surface of the heart (the side closest to your back).

- Locate the stumps of two relatively thin-walled blood vessels that enter the right atrium.
- Demonstrate this connection by passing a slender probe through them.
- The upper vessel is the *superior vena cava*, and the lower one is the *inferior vena cava*.

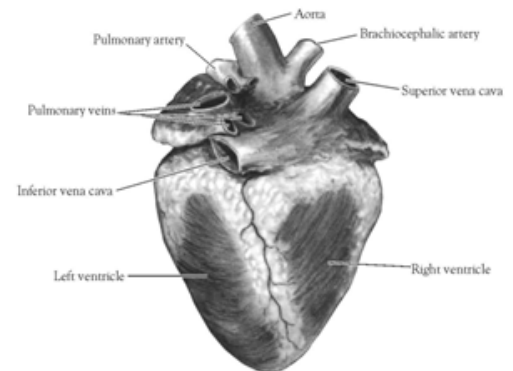


Figure 2. Heart (Posterior View)

10. Open the *right atrium*. To do this, follow these steps:

- Insert a blade of the scissors into the *superior vena cava* and cut downward through the atrial wall.
- Open the chamber, locate the *tricuspid valve* and examine its cusps.
- Run some water through the tricuspid valve to fill the chamber of the *right ventricle*.
- Gently squeeze the ventricles and watch the cusps of the valve as the water moves up against them.

11. Open the *right ventricle* as follows:

- a. Continue cutting downward through the *tricuspid valve* and the *right ventricular wall* until you reach the apex of the heart.
- b. Find the opening to the *pulmonary trunk* and use the scissors to cut upward through the wall of the *right ventricle*. Follow the pulmonary trunk until you have exposed the *pulmonary valve*.
- c. Examine the valve and its cusps.

12. Open the left side of the heart. To do this, follow these steps:

- a. Insert the blade of the scissors through the wall of the *left atrium* and cut downward to the apex of the heart.
- b. Open the *left atrium* and locate the four openings of the *pulmonary veins*. Pass a slender probe through each opening and locate the stump of its vessel.
- c. Examine the *bicuspid valve* (mitral valve) and its cusps.
- d. Also examine the *left ventricle* and compare the thickness of its wall with that of the *right ventricle*.

13. Locate the *aorta*, which leads away from the *left ventricle*, and proceed as follows:

- a. Compare the thickness of the *aortic wall* with that of the *pulmonary trunk*.
- b. Use scissors to cut along the length of the *aorta* to expose the *aortic valve* at its base.
- c. Examine the cusps of the valve and locate the openings of the *coronary arteries* just distal to them.

Questions

1. How many chambers are found in the mammalian heart? List these chambers.
2. Which chambers are the pumping chambers of the heart?
3. Which chambers are the receiving chambers of the heart?

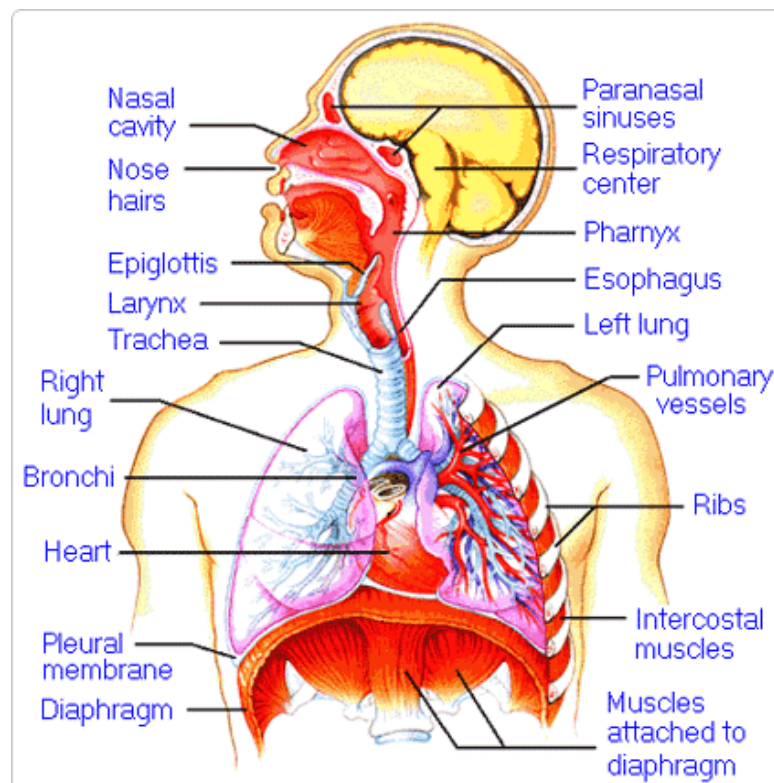
4. How do the walls of the atria compare with the walls of the ventricles and why are they different?

5. What is the purpose of heart valves?

6. Vessels that carry blood away from the heart are called _____, while _____ carry blood toward the heart.

7. Which artery is the largest and why?

8. How are the heart and lungs' function(s) related?

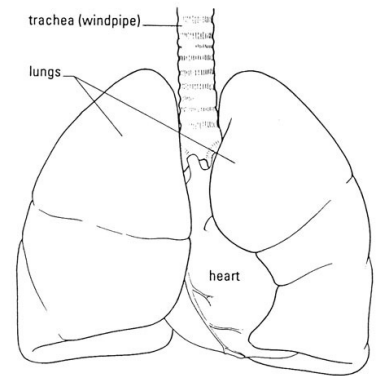


LAB - Dissection of Sheep's Pluck

Purpose: Today we will be exploring the structures of the respiratory system. We will also be examining how our lungs move as we breathe. Lastly, we will be describing how the structure of the lungs relate to how we breathe.

Procedure:

1. When handling the sheep's pluck, make sure to wear disposable gloves. Aprons and goggles are also available for additional protection.
2. Examine your specimen. Describe the color, shape, size, and feel of the specimen.
3. What organs/body parts are included in your specimen?
4. Identify the trachea. Is the trachea stiff or flexible? What allows the trachea to stay open and bend? Why is this important?
5. Try to inflate the lungs and observe how they respond. Do not breathe directly into the trachea to do this! Insert a length of rubber tubing into the trachea and attach it to a bellows or foot pump to inflate the lungs and then watch them deflate. It is best not to breathe through the tube into the lungs yourself because of the elastic recoil of the lung tissue: you might inhale a blast of rather unpleasant air!
 - a. What happened to the lungs when air was forced into them?
 - b. Do you think there is a limit to how much air can be pumped into the lungs? Explain your answer
5. Start of cut down the trachea with your dissecting scissors. Does the trachea stay as one tube or does it split as it enters the lung?



6. If the larynx is still attached to your lungs, try forcing air through the larynx while you squeeze it tight. As air moves past the skin and cords in the larynx it may make a noise.

Discuss how similar this is to the noise the animal makes in life.

7. Cut a small piece of spongy lung tissue to examine more closely.

- Are the lungs hollow bags or spongy? _____
- What does the lung tissue look like where you cut into it? _____
- Drop the piece of lung into a beaker of water. Does the piece sink or float? _____
- What does the answer to part c indicate? _____

8. Now let's examine the heart as review. Use a scalpel to remove a portion of this layer and expose the *myocardium* beneath.

- Note the abundance of fat along the paths of various blood vessels. This adipose tissue occurs in the loose connective tissue that underlies the visceral pericardium.
- Identify the following: ***Right Atrium, Right Ventricle, Pulmonary Artery, Left Atrium, Left Ventricle, and the Aorta***

9. Examine the dorsal surface of the heart (the side closest to your back).

- Locate the stumps of two relatively thin-walled blood vessels that enter the right atrium.
- Demonstrate this connection by passing a slender probe through them.
- The upper vessel is the *superior vena cava*, and the lower one is the *inferior vena cava*.

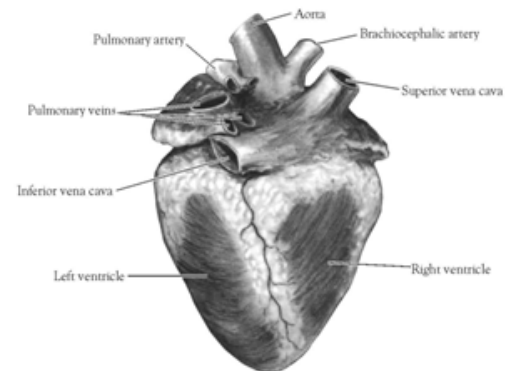


Figure 2. Heart (Posterior View)

10. Open the *right atrium*. To do this, follow these steps:

- Insert a blade of the scissors into the *superior vena cava* and cut downward through the atrial wall.
- Open the chamber, locate the *tricuspid valve* and examine its cusps.
- Run some water through the tricuspid valve to fill the chamber of the *right ventricle*.
- Gently squeeze the ventricles and watch the cusps of the valve as the water moves up against them.

11. Open the *right ventricle* as follows:

- a. Continue cutting downward through the *tricuspid valve* and the *right ventricular wall* until you reach the apex of the heart.
- b. Find the opening to the *pulmonary trunk* and use the scissors to cut upward through the wall of the *right ventricle*. Follow the pulmonary trunk until you have exposed the *pulmonary valve*.
- c. Examine the valve and its cusps.

12. Open the left side of the heart. To do this, follow these steps:

- a. Insert the blade of the scissors through the wall of the *left atrium* and cut downward to the apex of the heart.
- b. Open the *left atrium* and locate the four openings of the *pulmonary veins*. Pass a slender probe through each opening and locate the stump of its vessel.
- c. Examine the *bicuspid valve* (mitral valve) and its cusps.
- d. Also examine the *left ventricle* and compare the thickness of its wall with that of the *right ventricle*.

13. Locate the *aorta*, which leads away from the *left ventricle*, and proceed as follows:

- a. Compare the thickness of the *aortic wall* with that of the *pulmonary trunk*.
- b. Use scissors to cut along the length of the *aorta* to expose the *aortic valve* at its base.
- c. Examine the cusps of the valve and locate the openings of the *coronary arteries* just distal to them.

Questions

1. How many chambers are found in the mammalian heart? List these chambers.
2. Which chambers are the pumping chambers of the heart?
3. Which chambers are the receiving chambers of the heart?

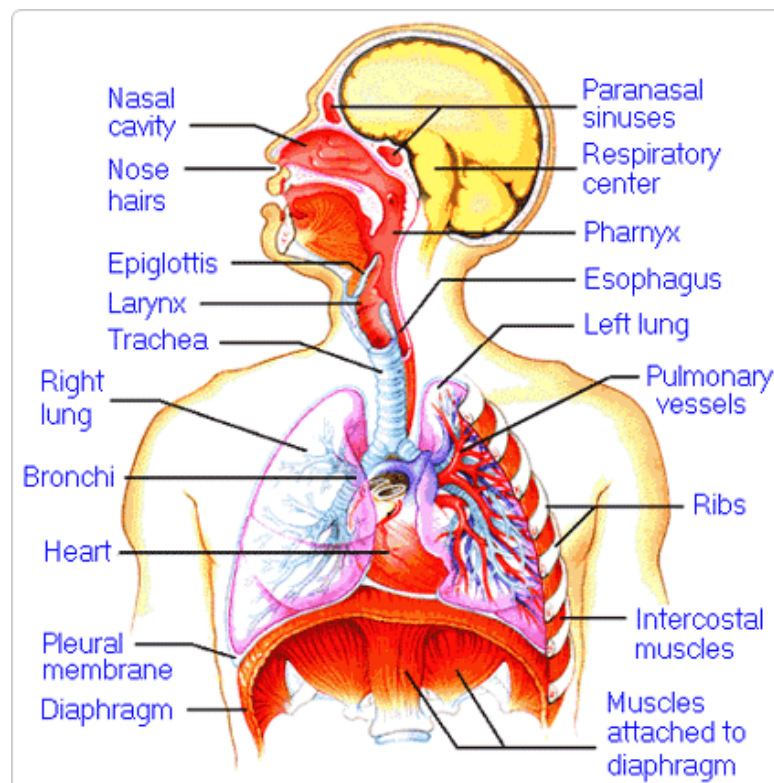
4. How do the walls of the atria compare with the walls of the ventricles and why are they different?

5. What is the purpose of heart valves?

6. Vessels that carry blood away from the heart are called _____, while _____ carry blood toward the heart.

7. Which artery is the largest and why?

8. How are the heart and lungs' function(s) related?

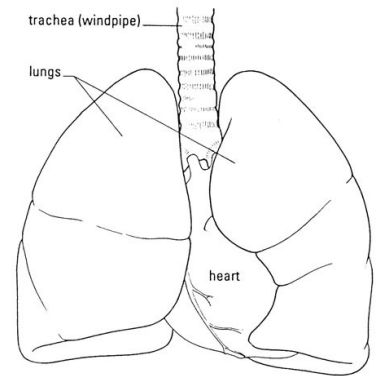


LAB - Dissection of Sheep's Pluck

Purpose: Today we will be exploring the structures of the respiratory system. We will also be examining how our lungs move as we breathe. Lastly, we will be describing how the structure of the lungs relate to how we breathe.

Procedure:

1. When handling the sheep's pluck, make sure to wear disposable gloves. Aprons and goggles are also available for additional protection.
2. Examine your specimen. Describe the color, shape, size, and feel of the specimen.
3. What organs/body parts are included in your specimen?
4. Identify the trachea. Is the trachea stiff or flexible? What allows the trachea to stay open and bend? Why is this important?
5. Try to inflate the lungs and observe how they respond. Do not breathe directly into the trachea to do this! Insert a length of rubber tubing into the trachea and attach it to a bellows or foot pump to inflate the lungs and then watch them deflate. It is best not to breathe through the tube into the lungs yourself because of the elastic recoil of the lung tissue: you might inhale a blast of rather unpleasant air!
 - a. What happened to the lungs when air was forced into them?
 - b. Do you think there is a limit to how much air can be pumped into the lungs? Explain your answer
5. Start of cut down the trachea with your dissecting scissors. Does the trachea stay as one tube or does it split as it enters the lung?



6. If the larynx is still attached to your lungs, try forcing air through the larynx while you squeeze it tight. As air moves past the skin and cords in the larynx it may make a noise.

Discuss how similar this is to the noise the animal makes in life.

7. Cut a small piece of spongy lung tissue to examine more closely.

- Are the lungs hollow bags or spongy? _____
- What does the lung tissue look like where you cut into it? _____
- Drop the piece of lung into a beaker of water. Does the piece sink or float? _____
- What does the answer to part c indicate? _____

8. Now let's examine the heart as review. Use a scalpel to remove a portion of this layer and expose the *myocardium* beneath.

- Note the abundance of fat along the paths of various blood vessels. This adipose tissue occurs in the loose connective tissue that underlies the visceral pericardium.
- Identify the following: ***Right Atrium, Right Ventricle, Pulmonary Artery, Left Atrium, Left Ventricle, and the Aorta***

9. Examine the dorsal surface of the heart (the side closest to your back).

- Locate the stumps of two relatively thin-walled blood vessels that enter the right atrium.
- Demonstrate this connection by passing a slender probe through them.
- The upper vessel is the *superior vena cava*, and the lower one is the *inferior vena cava*.

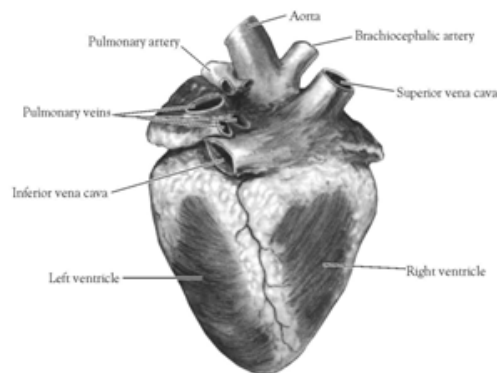


Figure 2. Heart (Posterior View)

10. Open the *right atrium*. To do this, follow these steps:

- Insert a blade of the scissors into the *superior vena cava* and cut downward through the atrial wall.
- Open the chamber, locate the *tricuspid valve* and examine its cusps.
- Run some water through the tricuspid valve to fill the chamber of the *right ventricle*.
- Gently squeeze the ventricles and watch the cusps of the valve as the water moves up against them.

11. Open the *right ventricle* as follows:

- a. Continue cutting downward through the *tricuspid valve* and the *right ventricular wall* until you reach the apex of the heart.
- b. Find the opening to the *pulmonary trunk* and use the scissors to cut upward through the wall of the *right ventricle*. Follow the pulmonary trunk until you have exposed the *pulmonary valve*.
- c. Examine the valve and its cusps.

12. Open the left side of the heart. To do this, follow these steps:

- a. Insert the blade of the scissors through the wall of the *left atrium* and cut downward to the apex of the heart.
- b. Open the *left atrium* and locate the four openings of the *pulmonary veins*. Pass a slender probe through each opening and locate the stump of its vessel.
- c. Examine the *bicuspid valve* (mitral valve) and its cusps.
- d. Also examine the *left ventricle* and compare the thickness of its wall with that of the *right ventricle*.

13. Locate the *aorta*, which leads away from the *left ventricle*, and proceed as follows:

- a. Compare the thickness of the *aortic wall* with that of the *pulmonary trunk*.
- b. Use scissors to cut along the length of the *aorta* to expose the *aortic valve* at its base.
- c. Examine the cusps of the valve and locate the openings of the *coronary arteries* just distal to them.

Questions

1. How many chambers are found in the mammalian heart? List these chambers.
2. Which chambers are the pumping chambers of the heart?
3. Which chambers are the receiving chambers of the heart?

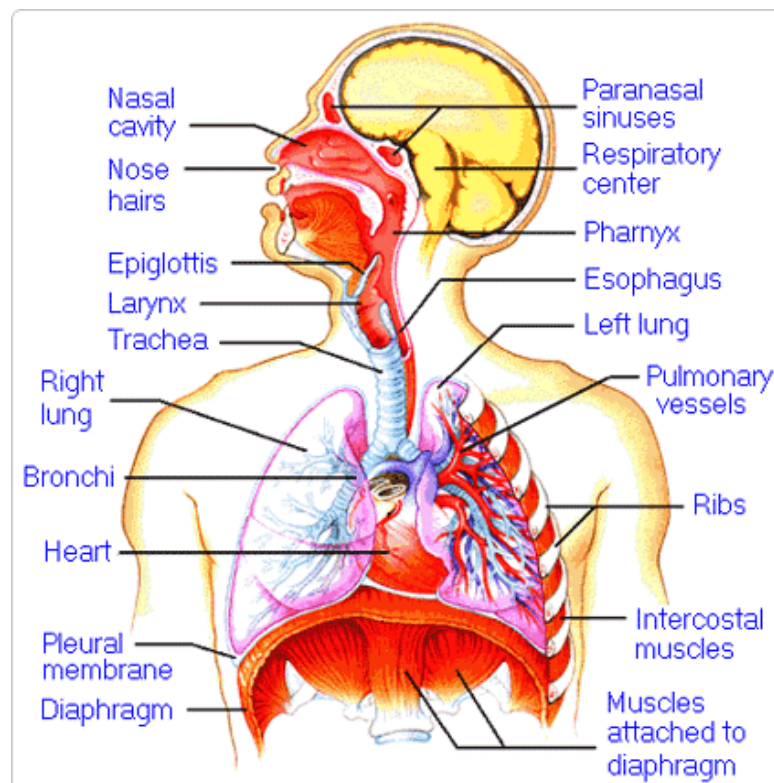
4. How do the walls of the atria compare with the walls of the ventricles and why are they different?

5. What is the purpose of heart valves?

6. Vessels that carry blood away from the heart are called _____, while _____ carry blood toward the heart.

7. Which artery is the largest and why?

8. How are the heart and lungs' function(s) related?

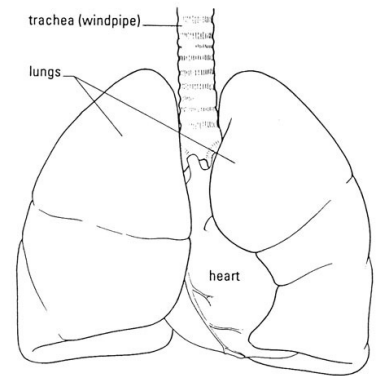


LAB - Dissection of Sheep's Pluck

Purpose: Today we will be exploring the structures of the respiratory system. We will also be examining how our lungs move as we breathe. Lastly, we will be describing how the structure of the lungs relate to how we breathe.

Procedure:

1. When handling the sheep's pluck, make sure to wear disposable gloves. Aprons and goggles are also available for additional protection.
2. Examine your specimen. Describe the color, shape, size, and feel of the specimen.
3. What organs/body parts are included in your specimen?
4. Identify the trachea. Is the trachea stiff or flexible? What allows the trachea to stay open and bend? Why is this important?
5. Try to inflate the lungs and observe how they respond. Do not breathe directly into the trachea to do this! Insert a length of rubber tubing into the trachea and attach it to a bellows or foot pump to inflate the lungs and then watch them deflate. It is best not to breathe through the tube into the lungs yourself because of the elastic recoil of the lung tissue: you might inhale a blast of rather unpleasant air!
 - a. What happened to the lungs when air was forced into them?
 - b. Do you think there is a limit to how much air can be pumped into the lungs? Explain your answer
5. Start of cut down the trachea with your dissecting scissors. Does the trachea stay as one tube or does it split as it enters the lung?



6. If the larynx is still attached to your lungs, try forcing air through the larynx while you squeeze it tight. As air moves past the skin and cords in the larynx it may make a noise.

Discuss how similar this is to the noise the animal makes in life.

7. Cut a small piece of spongy lung tissue to examine more closely.

- Are the lungs hollow bags or spongy? _____
- What does the lung tissue look like where you cut into it? _____
- Drop the piece of lung into a beaker of water. Does the piece sink or float? _____
- What does the answer to part c indicate? _____

8. Now let's examine the heart as review. Use a scalpel to remove a portion of this layer and expose the *myocardium* beneath.

- Note the abundance of fat along the paths of various blood vessels. This adipose tissue occurs in the loose connective tissue that underlies the visceral pericardium.
- Identify the following: ***Right Atrium, Right Ventricle, Pulmonary Artery, Left Atrium, Left Ventricle, and the Aorta***

9. Examine the dorsal surface of the heart (the side closest to your back).

- Locate the stumps of two relatively thin-walled blood vessels that enter the right atrium.
- Demonstrate this connection by passing a slender probe through them.
- The upper vessel is the *superior vena cava*, and the lower one is the *inferior vena cava*.

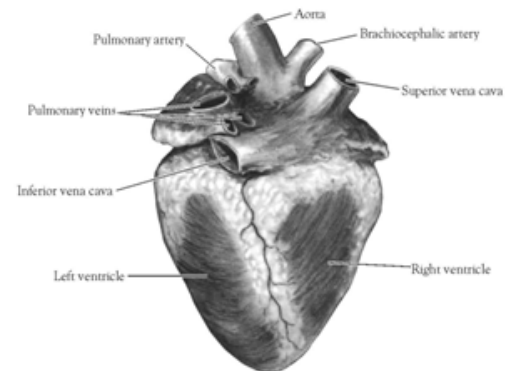


Figure 2. Heart (Posterior View)

10. Open the *right atrium*. To do this, follow these steps:

- Insert a blade of the scissors into the *superior vena cava* and cut downward through the atrial wall.
- Open the chamber, locate the *tricuspid valve* and examine its cusps.
- Run some water through the tricuspid valve to fill the chamber of the *right ventricle*.
- Gently squeeze the ventricles and watch the cusps of the valve as the water moves up against them.

11. Open the *right ventricle* as follows:

- a. Continue cutting downward through the *tricuspid valve* and the *right ventricular wall* until you reach the apex of the heart.
- b. Find the opening to the *pulmonary trunk* and use the scissors to cut upward through the wall of the *right ventricle*. Follow the pulmonary trunk until you have exposed the *pulmonary valve*.
- c. Examine the valve and its cusps.

12. Open the left side of the heart. To do this, follow these steps:

- a. Insert the blade of the scissors through the wall of the *left atrium* and cut downward to the apex of the heart.
- b. Open the *left atrium* and locate the four openings of the *pulmonary veins*. Pass a slender probe through each opening and locate the stump of its vessel.
- c. Examine the *bicuspid valve* (mitral valve) and its cusps.
- d. Also examine the *left ventricle* and compare the thickness of its wall with that of the *right ventricle*.

13. Locate the *aorta*, which leads away from the *left ventricle*, and proceed as follows:

- a. Compare the thickness of the *aortic wall* with that of the *pulmonary trunk*.
- b. Use scissors to cut along the length of the *aorta* to expose the *aortic valve* at its base.
- c. Examine the cusps of the valve and locate the openings of the *coronary arteries* just distal to them.

Questions

1. How many chambers are found in the mammalian heart? List these chambers.
2. Which chambers are the pumping chambers of the heart?
3. Which chambers are the receiving chambers of the heart?

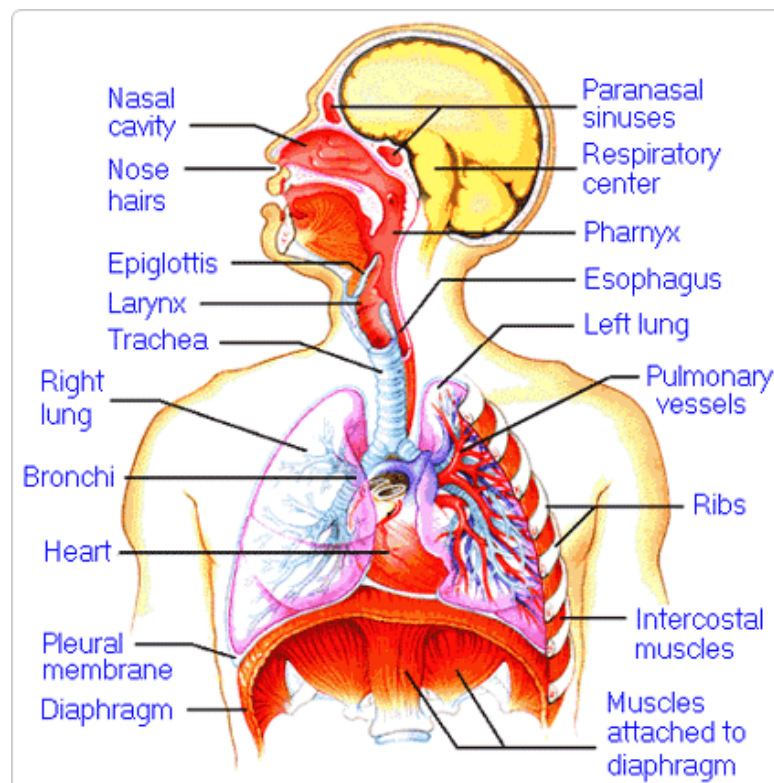
4. How do the walls of the atria compare with the walls of the ventricles and why are they different?

5. What is the purpose of heart valves?

6. Vessels that carry blood away from the heart are called _____, while _____ carry blood toward the heart.

7. Which artery is the largest and why?

8. How are the heart and lungs' function(s) related?

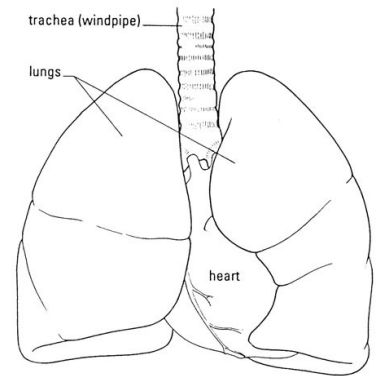


LAB - Dissection of Sheep's Pluck

Purpose: Today we will be exploring the structures of the respiratory system. We will also be examining how our lungs move as we breathe. Lastly, we will be describing how the structure of the lungs relate to how we breathe.

Procedure:

1. When handling the sheep's pluck, make sure to wear disposable gloves. Aprons and goggles are also available for additional protection.
2. Examine your specimen. Describe the color, shape, size, and feel of the specimen.
3. What organs/body parts are included in your specimen?
4. Identify the trachea. Is the trachea stiff or flexible? What allows the trachea to stay open and bend? Why is this important?
5. Try to inflate the lungs and observe how they respond. Do not breathe directly into the trachea to do this! Insert a length of rubber tubing into the trachea and attach it to a bellows or foot pump to inflate the lungs and then watch them deflate. It is best not to breathe through the tube into the lungs yourself because of the elastic recoil of the lung tissue: you might inhale a blast of rather unpleasant air!
 - a. What happened to the lungs when air was forced into them?
 - b. Do you think there is a limit to how much air can be pumped into the lungs? Explain your answer
5. Start of cut down the trachea with your dissecting scissors. Does the trachea stay as one tube or does it split as it enters the lung?



6. If the larynx is still attached to your lungs, try forcing air through the larynx while you squeeze it tight. As air moves past the skin and cords in the larynx it may make a noise.

Discuss how similar this is to the noise the animal makes in life.

7. Cut a small piece of spongy lung tissue to examine more closely.

- Are the lungs hollow bags or spongy? _____
- What does the lung tissue look like where you cut into it? _____
- Drop the piece of lung into a beaker of water. Does the piece sink or float? _____
- What does the answer to part c indicate? _____

8. Now let's examine the heart as review. Use a scalpel to remove a portion of this layer and expose the *myocardium* beneath.

- Note the abundance of fat along the paths of various blood vessels. This adipose tissue occurs in the loose connective tissue that underlies the visceral pericardium.
- Identify the following: ***Right Atrium, Right Ventricle, Pulmonary Artery, Left Atrium, Left Ventricle, and the Aorta***

9. Examine the dorsal surface of the heart (the side closest to your back).

- Locate the stumps of two relatively thin-walled blood vessels that enter the right atrium.
- Demonstrate this connection by passing a slender probe through them.
- The upper vessel is the *superior vena cava*, and the lower one is the *inferior vena cava*.

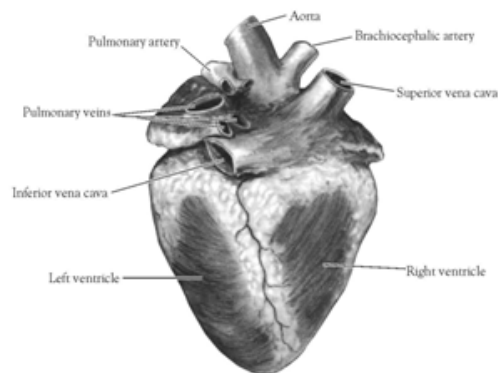


Figure 2. Heart (Posterior View)

10. Open the *right atrium*. To do this, follow these steps:

- Insert a blade of the scissors into the *superior vena cava* and cut downward through the atrial wall.
- Open the chamber, locate the *tricuspid valve* and examine its cusps.
- Run some water through the tricuspid valve to fill the chamber of the *right ventricle*.
- Gently squeeze the ventricles and watch the cusps of the valve as the water moves up against them.

11. Open the *right ventricle* as follows:

- a. Continue cutting downward through the *tricuspid valve* and the *right ventricular wall* until you reach the apex of the heart.
- b. Find the opening to the *pulmonary trunk* and use the scissors to cut upward through the wall of the *right ventricle*. Follow the pulmonary trunk until you have exposed the *pulmonary valve*.
- c. Examine the valve and its cusps.

12. Open the left side of the heart. To do this, follow these steps:

- a. Insert the blade of the scissors through the wall of the *left atrium* and cut downward to the apex of the heart.
- b. Open the *left atrium* and locate the four openings of the *pulmonary veins*. Pass a slender probe through each opening and locate the stump of its vessel.
- c. Examine the *bicuspid valve* (mitral valve) and its cusps.
- d. Also examine the *left ventricle* and compare the thickness of its wall with that of the *right ventricle*.

13. Locate the *aorta*, which leads away from the *left ventricle*, and proceed as follows:

- a. Compare the thickness of the *aortic wall* with that of the *pulmonary trunk*.
- b. Use scissors to cut along the length of the *aorta* to expose the *aortic valve* at its base.
- c. Examine the cusps of the valve and locate the openings of the *coronary arteries* just distal to them.

Questions

1. How many chambers are found in the mammalian heart? List these chambers.
2. Which chambers are the pumping chambers of the heart?
3. Which chambers are the receiving chambers of the heart?

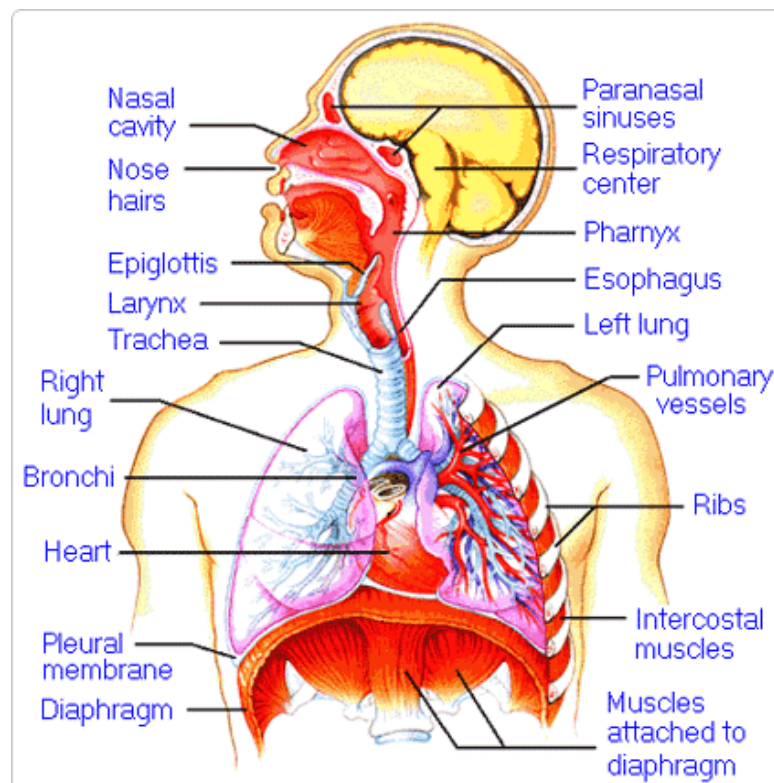
4. How do the walls of the atria compare with the walls of the ventricles and why are they different?

5. What is the purpose of heart valves?

6. Vessels that carry blood away from the heart are called _____, while _____ carry blood toward the heart.

7. Which artery is the largest and why?

8. How are the heart and lungs' function(s) related?

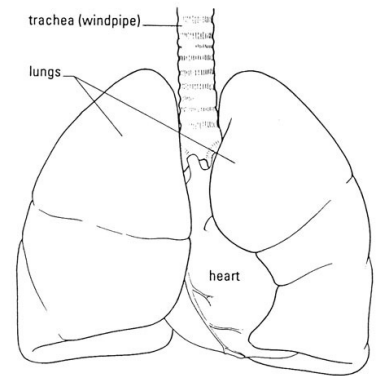


LAB - Dissection of Sheep's Pluck

Purpose: Today we will be exploring the structures of the respiratory system. We will also be examining how our lungs move as we breathe. Lastly, we will be describing how the structure of the lungs relate to how we breathe.

Procedure:

1. When handling the sheep's pluck, make sure to wear disposable gloves. Aprons and goggles are also available for additional protection.
2. Examine your specimen. Describe the color, shape, size, and feel of the specimen.
3. What organs/body parts are included in your specimen?
4. Identify the trachea. Is the trachea stiff or flexible? What allows the trachea to stay open and bend? Why is this important?
5. Try to inflate the lungs and observe how they respond. Do not breathe directly into the trachea to do this! Insert a length of rubber tubing into the trachea and attach it to a bellows or foot pump to inflate the lungs and then watch them deflate. It is best not to breathe through the tube into the lungs yourself because of the elastic recoil of the lung tissue: you might inhale a blast of rather unpleasant air!
 - a. What happened to the lungs when air was forced into them?
 - b. Do you think there is a limit to how much air can be pumped into the lungs? Explain your answer
5. Start of cut down the trachea with your dissecting scissors. Does the trachea stay as one tube or does it split as it enters the lung?



6. If the larynx is still attached to your lungs, try forcing air through the larynx while you squeeze it tight. As air moves past the skin and cords in the larynx it may make a noise.

Discuss how similar this is to the noise the animal makes in life.

7. Cut a small piece of spongy lung tissue to examine more closely.

- Are the lungs hollow bags or spongy? _____
- What does the lung tissue look like where you cut into it? _____
- Drop the piece of lung into a beaker of water. Does the piece sink or float? _____
- What does the answer to part c indicate? _____

8. Now let's examine the heart as review. Use a scalpel to remove a portion of this layer and expose the *myocardium* beneath.

- Note the abundance of fat along the paths of various blood vessels. This adipose tissue occurs in the loose connective tissue that underlies the visceral pericardium.
- Identify the following: ***Right Atrium, Right Ventricle, Pulmonary Artery, Left Atrium, Left Ventricle, and the Aorta***

9. Examine the dorsal surface of the heart (the side closest to your back).

- Locate the stumps of two relatively thin-walled blood vessels that enter the right atrium.
- Demonstrate this connection by passing a slender probe through them.
- The upper vessel is the *superior vena cava*, and the lower one is the *inferior vena cava*.

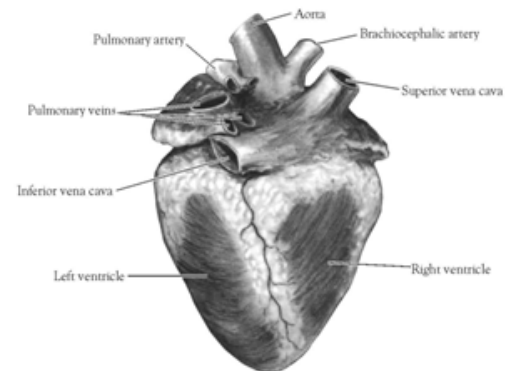


Figure 2. Heart (Posterior View)

10. Open the *right atrium*. To do this, follow these steps:

- Insert a blade of the scissors into the *superior vena cava* and cut downward through the atrial wall.
- Open the chamber, locate the *tricuspid valve* and examine its cusps.
- Run some water through the tricuspid valve to fill the chamber of the *right ventricle*.
- Gently squeeze the ventricles and watch the cusps of the valve as the water moves up against them.

11. Open the *right ventricle* as follows:

- a. Continue cutting downward through the *tricuspid valve* and the *right ventricular wall* until you reach the apex of the heart.
- b. Find the opening to the *pulmonary trunk* and use the scissors to cut upward through the wall of the *right ventricle*. Follow the pulmonary trunk until you have exposed the *pulmonary valve*.
- c. Examine the valve and its cusps.

12. Open the left side of the heart. To do this, follow these steps:

- a. Insert the blade of the scissors through the wall of the *left atrium* and cut downward to the apex of the heart.
- b. Open the *left atrium* and locate the four openings of the *pulmonary veins*. Pass a slender probe through each opening and locate the stump of its vessel.
- c. Examine the *bicuspid valve* (mitral valve) and its cusps.
- d. Also examine the *left ventricle* and compare the thickness of its wall with that of the *right ventricle*.

13. Locate the *aorta*, which leads away from the *left ventricle*, and proceed as follows:

- a. Compare the thickness of the *aortic wall* with that of the *pulmonary trunk*.
- b. Use scissors to cut along the length of the *aorta* to expose the *aortic valve* at its base.
- c. Examine the cusps of the valve and locate the openings of the *coronary arteries* just distal to them.

Questions

1. How many chambers are found in the mammalian heart? List these chambers.
2. Which chambers are the pumping chambers of the heart?
3. Which chambers are the receiving chambers of the heart?

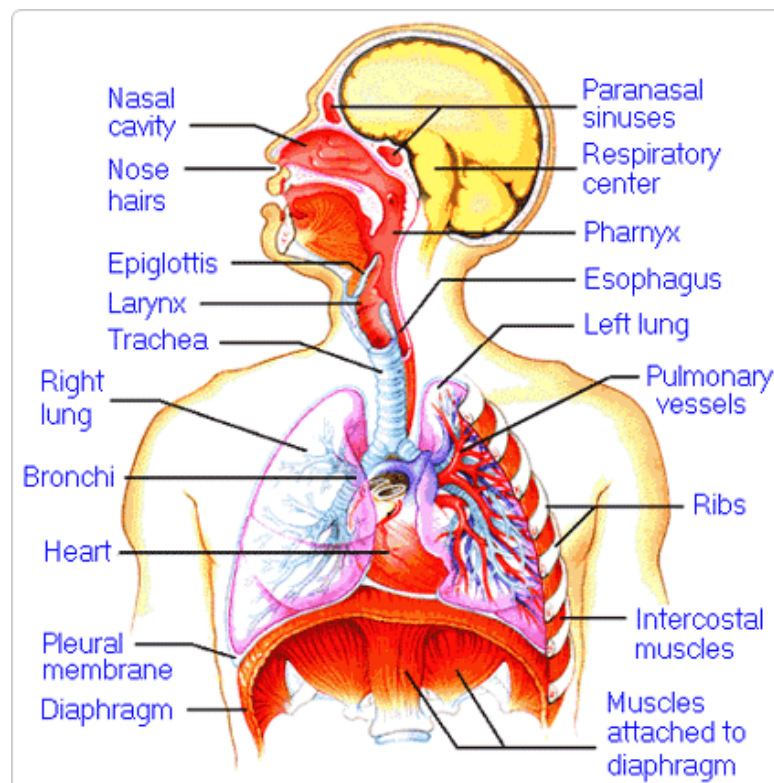
4. How do the walls of the atria compare with the walls of the ventricles and why are they different?

5. What is the purpose of heart valves?

6. Vessels that carry blood away from the heart are called _____, while _____ carry blood toward the heart.

7. Which artery is the largest and why?

8. How are the heart and lungs' function(s) related?

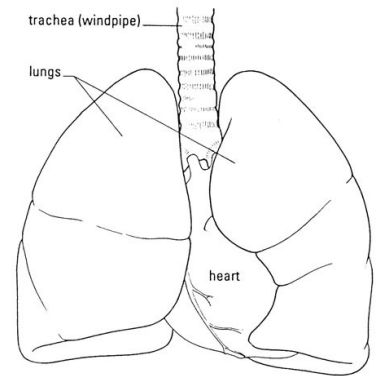


LAB - Dissection of Sheep's Pluck

Purpose: Today we will be exploring the structures of the respiratory system. We will also be examining how our lungs move as we breathe. Lastly, we will be describing how the structure of the lungs relate to how we breathe.

Procedure:

1. When handling the sheep's pluck, make sure to wear disposable gloves. Aprons and goggles are also available for additional protection.
2. Examine your specimen. Describe the color, shape, size, and feel of the specimen.
3. What organs/body parts are included in your specimen?
4. Identify the trachea. Is the trachea stiff or flexible? What allows the trachea to stay open and bend? Why is this important?
5. Try to inflate the lungs and observe how they respond. Do not breathe directly into the trachea to do this! Insert a length of rubber tubing into the trachea and attach it to a bellows or foot pump to inflate the lungs and then watch them deflate. It is best not to breathe through the tube into the lungs yourself because of the elastic recoil of the lung tissue: you might inhale a blast of rather unpleasant air!
 - a. What happened to the lungs when air was forced into them?
 - b. Do you think there is a limit to how much air can be pumped into the lungs? Explain your answer
5. Start of cut down the trachea with your dissecting scissors. Does the trachea stay as one tube or does it split as it enters the lung?



6. If the larynx is still attached to your lungs, try forcing air through the larynx while you squeeze it tight. As air moves past the skin and cords in the larynx it may make a noise.

Discuss how similar this is to the noise the animal makes in life.

7. Cut a small piece of spongy lung tissue to examine more closely.

- Are the lungs hollow bags or spongy? _____
- What does the lung tissue look like where you cut into it? _____
- Drop the piece of lung into a beaker of water. Does the piece sink or float? _____
- What does the answer to part c indicate? _____

8. Now let's examine the heart as review. Use a scalpel to remove a portion of this layer and expose the *myocardium* beneath.

- Note the abundance of fat along the paths of various blood vessels. This adipose tissue occurs in the loose connective tissue that underlies the visceral pericardium.
- Identify the following: ***Right Atrium, Right Ventricle, Pulmonary Artery, Left Atrium, Left Ventricle, and the Aorta***

9. Examine the dorsal surface of the heart (the side closest to your back).

- Locate the stumps of two relatively thin-walled blood vessels that enter the right atrium.
- Demonstrate this connection by passing a slender probe through them.
- The upper vessel is the *superior vena cava*, and the lower one is the *inferior vena cava*.

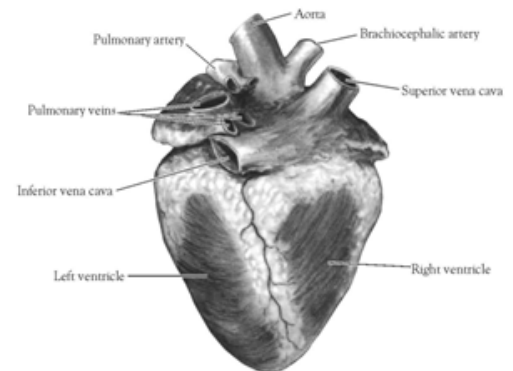


Figure 2. Heart (Posterior View)

10. Open the *right atrium*. To do this, follow these steps:

- Insert a blade of the scissors into the *superior vena cava* and cut downward through the atrial wall.
- Open the chamber, locate the *tricuspid valve* and examine its cusps.
- Run some water through the tricuspid valve to fill the chamber of the *right ventricle*.
- Gently squeeze the ventricles and watch the cusps of the valve as the water moves up against them.

11. Open the *right ventricle* as follows:

- a. Continue cutting downward through the *tricuspid valve* and the *right ventricular wall* until you reach the apex of the heart.
- b. Find the opening to the *pulmonary trunk* and use the scissors to cut upward through the wall of the *right ventricle*. Follow the pulmonary trunk until you have exposed the *pulmonary valve*.
- c. Examine the valve and its cusps.

12. Open the left side of the heart. To do this, follow these steps:

- a. Insert the blade of the scissors through the wall of the *left atrium* and cut downward to the apex of the heart.
- b. Open the *left atrium* and locate the four openings of the *pulmonary veins*. Pass a slender probe through each opening and locate the stump of its vessel.
- c. Examine the *bicuspid valve* (mitral valve) and its cusps.
- d. Also examine the *left ventricle* and compare the thickness of its wall with that of the *right ventricle*.

13. Locate the *aorta*, which leads away from the *left ventricle*, and proceed as follows:

- a. Compare the thickness of the *aortic wall* with that of the *pulmonary trunk*.
- b. Use scissors to cut along the length of the *aorta* to expose the *aortic valve* at its base.
- c. Examine the cusps of the valve and locate the openings of the *coronary arteries* just distal to them.

Questions

1. How many chambers are found in the mammalian heart? List these chambers.
2. Which chambers are the pumping chambers of the heart?
3. Which chambers are the receiving chambers of the heart?

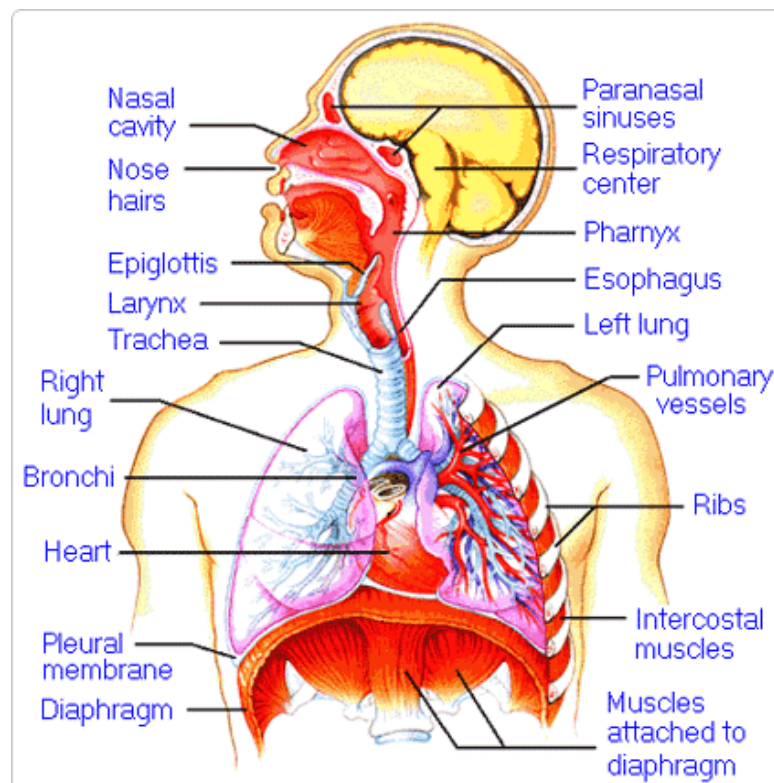
4. How do the walls of the atria compare with the walls of the ventricles and why are they different?

5. What is the purpose of heart valves?

6. Vessels that carry blood away from the heart are called _____, while _____ carry blood toward the heart.

7. Which artery is the largest and why?

8. How are the heart and lungs' function(s) related?

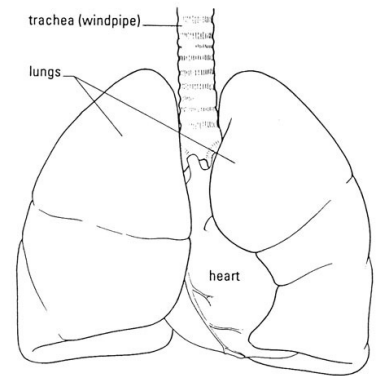


LAB - Dissection of Sheep's Pluck

Purpose: Today we will be exploring the structures of the respiratory system. We will also be examining how our lungs move as we breathe. Lastly, we will be describing how the structure of the lungs relate to how we breathe.

Procedure:

1. When handling the sheep's pluck, make sure to wear disposable gloves. Aprons and goggles are also available for additional protection.
2. Examine your specimen. Describe the color, shape, size, and feel of the specimen.
3. What organs/body parts are included in your specimen?
4. Identify the trachea. Is the trachea stiff or flexible? What allows the trachea to stay open and bend? Why is this important?
5. Try to inflate the lungs and observe how they respond. Do not breathe directly into the trachea to do this! Insert a length of rubber tubing into the trachea and attach it to a bellows or foot pump to inflate the lungs and then watch them deflate. It is best not to breathe through the tube into the lungs yourself because of the elastic recoil of the lung tissue: you might inhale a blast of rather unpleasant air!
 - a. What happened to the lungs when air was forced into them?
 - b. Do you think there is a limit to how much air can be pumped into the lungs? Explain your answer
5. Start of cut down the trachea with your dissecting scissors. Does the trachea stay as one tube or does it split as it enters the lung?



6. If the larynx is still attached to your lungs, try forcing air through the larynx while you squeeze it tight. As air moves past the skin and cords in the larynx it may make a noise.

Discuss how similar this is to the noise the animal makes in life.

7. Cut a small piece of spongy lung tissue to examine more closely.

- Are the lungs hollow bags or spongy? _____
- What does the lung tissue look like where you cut into it? _____
- Drop the piece of lung into a beaker of water. Does the piece sink or float? _____
- What does the answer to part c indicate? _____

8. Now let's examine the heart as review. Use a scalpel to remove a portion of this layer and expose the *myocardium* beneath.

- Note the abundance of fat along the paths of various blood vessels. This adipose tissue occurs in the loose connective tissue that underlies the visceral pericardium.
- Identify the following: ***Right Atrium, Right Ventricle, Pulmonary Artery, Left Atrium, Left Ventricle, and the Aorta***

9. Examine the dorsal surface of the heart (the side closest to your back).

- Locate the stumps of two relatively thin-walled blood vessels that enter the right atrium.
- Demonstrate this connection by passing a slender probe through them.
- The upper vessel is the *superior vena cava*, and the lower one is the *inferior vena cava*.

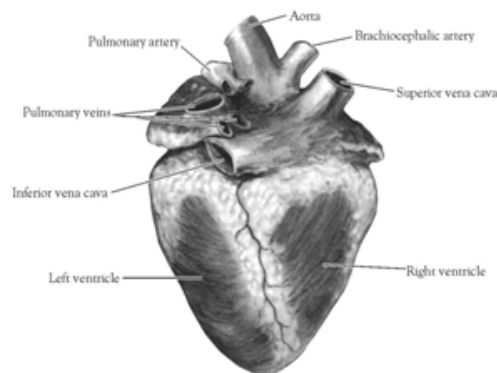


Figure 2. Heart (Posterior View)

10. Open the *right atrium*. To do this, follow these steps:

- Insert a blade of the scissors into the *superior vena cava* and cut downward through the atrial wall.
- Open the chamber, locate the *tricuspid valve* and examine its cusps.
- Run some water through the tricuspid valve to fill the chamber of the *right ventricle*.
- Gently squeeze the ventricles and watch the cusps of the valve as the water moves up against them.

11. Open the *right ventricle* as follows:

- a. Continue cutting downward through the *tricuspid valve* and the *right ventricular wall* until you reach the apex of the heart.
- b. Find the opening to the *pulmonary trunk* and use the scissors to cut upward through the wall of the *right ventricle*. Follow the pulmonary trunk until you have exposed the *pulmonary valve*.
- c. Examine the valve and its cusps.

12. Open the left side of the heart. To do this, follow these steps:

- a. Insert the blade of the scissors through the wall of the *left atrium* and cut downward to the apex of the heart.
- b. Open the *left atrium* and locate the four openings of the *pulmonary veins*. Pass a slender probe through each opening and locate the stump of its vessel.
- c. Examine the *bicuspid valve* (mitral valve) and its cusps.
- d. Also examine the *left ventricle* and compare the thickness of its wall with that of the *right ventricle*.

13. Locate the *aorta*, which leads away from the *left ventricle*, and proceed as follows:

- a. Compare the thickness of the *aortic wall* with that of the *pulmonary trunk*.
- b. Use scissors to cut along the length of the *aorta* to expose the *aortic valve* at its base.
- c. Examine the cusps of the valve and locate the openings of the *coronary arteries* just distal to them.

Questions

1. How many chambers are found in the mammalian heart? List these chambers.
2. Which chambers are the pumping chambers of the heart?
3. Which chambers are the receiving chambers of the heart?

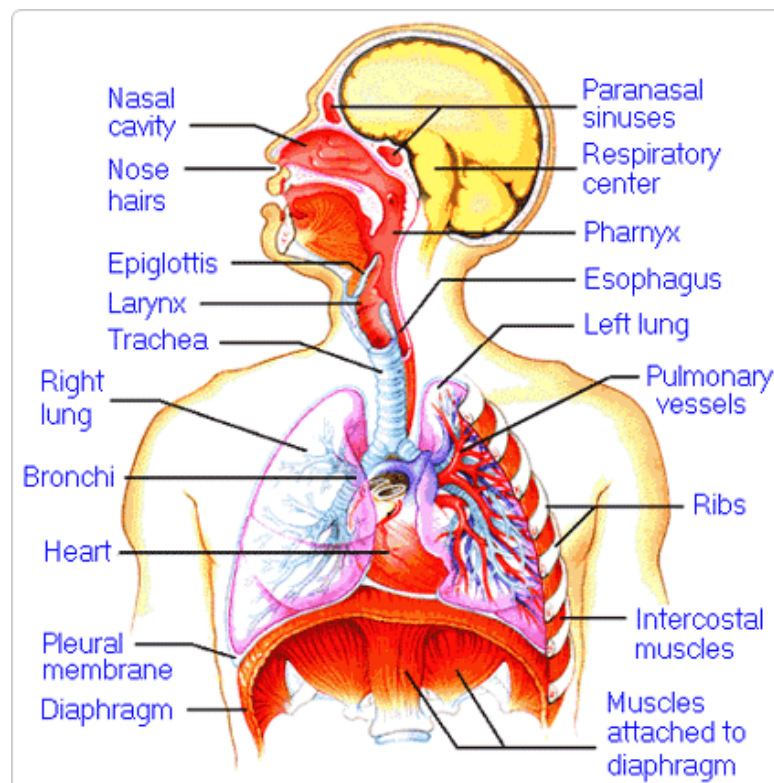
4. How do the walls of the atria compare with the walls of the ventricles and why are they different?

5. What is the purpose of heart valves?

6. Vessels that carry blood away from the heart are called _____, while _____ carry blood toward the heart.

7. Which artery is the largest and why?

8. How are the heart and lungs' function(s) related?

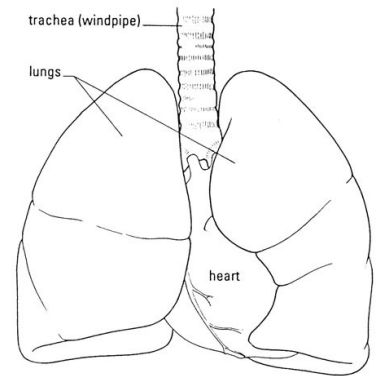


LAB - Dissection of Sheep's Pluck

Purpose: Today we will be exploring the structures of the respiratory system. We will also be examining how our lungs move as we breathe. Lastly, we will be describing how the structure of the lungs relate to how we breathe.

Procedure:

1. When handling the sheep's pluck, make sure to wear disposable gloves. Aprons and goggles are also available for additional protection.
2. Examine your specimen. Describe the color, shape, size, and feel of the specimen.
3. What organs/body parts are included in your specimen?
4. Identify the trachea. Is the trachea stiff or flexible? What allows the trachea to stay open and bend? Why is this important?
5. Try to inflate the lungs and observe how they respond. Do not breathe directly into the trachea to do this! Insert a length of rubber tubing into the trachea and attach it to a bellows or foot pump to inflate the lungs and then watch them deflate. It is best not to breathe through the tube into the lungs yourself because of the elastic recoil of the lung tissue: you might inhale a blast of rather unpleasant air!
 - a. What happened to the lungs when air was forced into them?
 - b. Do you think there is a limit to how much air can be pumped into the lungs? Explain your answer
5. Start of cut down the trachea with your dissecting scissors. Does the trachea stay as one tube or does it split as it enters the lung?



6. If the larynx is still attached to your lungs, try forcing air through the larynx while you squeeze it tight. As air moves past the skin and cords in the larynx it may make a noise.

Discuss how similar this is to the noise the animal makes in life.

7. Cut a small piece of spongy lung tissue to examine more closely.

- Are the lungs hollow bags or spongy? _____
- What does the lung tissue look like where you cut into it? _____
- Drop the piece of lung into a beaker of water. Does the piece sink or float? _____
- What does the answer to part c indicate? _____

8. Now let's examine the heart as review. Use a scalpel to remove a portion of this layer and expose the *myocardium* beneath.

- Note the abundance of fat along the paths of various blood vessels. This adipose tissue occurs in the loose connective tissue that underlies the visceral pericardium.
- Identify the following: ***Right Atrium, Right Ventricle, Pulmonary Artery, Left Atrium, Left Ventricle, and the Aorta***

9. Examine the dorsal surface of the heart (the side closest to your back).

- Locate the stumps of two relatively thin-walled blood vessels that enter the right atrium.
- Demonstrate this connection by passing a slender probe through them.
- The upper vessel is the *superior vena cava*, and the lower one is the *inferior vena cava*.

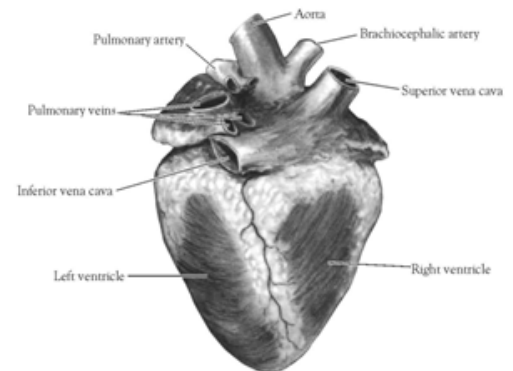


Figure 2. Heart (Posterior View)

10. Open the *right atrium*. To do this, follow these steps:

- Insert a blade of the scissors into the *superior vena cava* and cut downward through the atrial wall.
- Open the chamber, locate the *tricuspid valve* and examine its cusps.
- Run some water through the tricuspid valve to fill the chamber of the *right ventricle*.
- Gently squeeze the ventricles and watch the cusps of the valve as the water moves up against them.

11. Open the *right ventricle* as follows:

- a. Continue cutting downward through the *tricuspid valve* and the *right ventricular wall* until you reach the apex of the heart.
- b. Find the opening to the *pulmonary trunk* and use the scissors to cut upward through the wall of the *right ventricle*. Follow the pulmonary trunk until you have exposed the *pulmonary valve*.
- c. Examine the valve and its cusps.

12. Open the left side of the heart. To do this, follow these steps:

- a. Insert the blade of the scissors through the wall of the *left atrium* and cut downward to the apex of the heart.
- b. Open the *left atrium* and locate the four openings of the *pulmonary veins*. Pass a slender probe through each opening and locate the stump of its vessel.
- c. Examine the *bicuspid valve* (mitral valve) and its cusps.
- d. Also examine the *left ventricle* and compare the thickness of its wall with that of the *right ventricle*.

13. Locate the *aorta*, which leads away from the *left ventricle*, and proceed as follows:

- a. Compare the thickness of the *aortic wall* with that of the *pulmonary trunk*.
- b. Use scissors to cut along the length of the *aorta* to expose the *aortic valve* at its base.
- c. Examine the cusps of the valve and locate the openings of the *coronary arteries* just distal to them.

Questions

1. How many chambers are found in the mammalian heart? List these chambers.
2. Which chambers are the pumping chambers of the heart?
3. Which chambers are the receiving chambers of the heart?

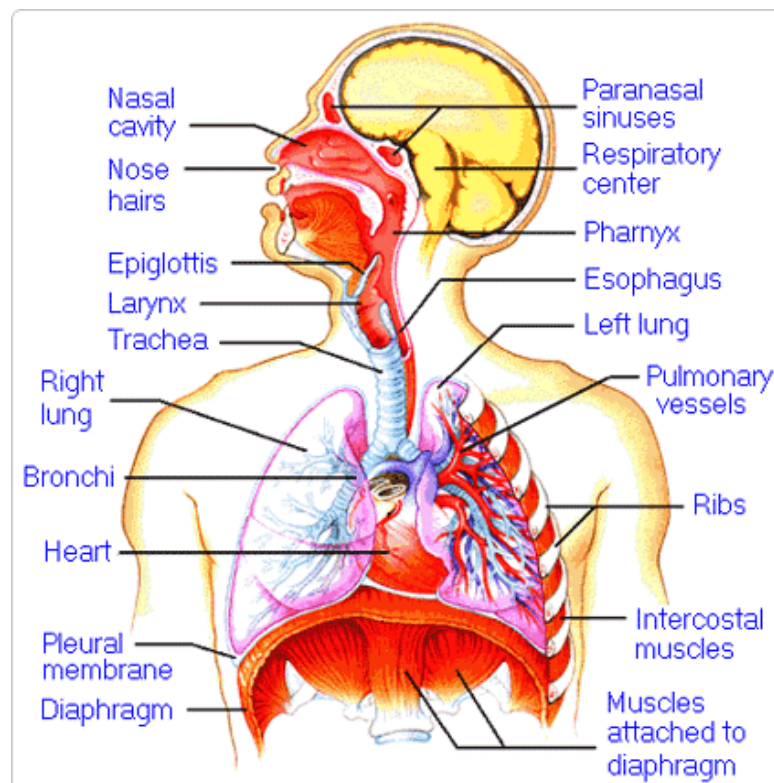
4. How do the walls of the atria compare with the walls of the ventricles and why are they different?

5. What is the purpose of heart valves?

6. Vessels that carry blood away from the heart are called _____, while _____ carry blood toward the heart.

7. Which artery is the largest and why?

8. How are the heart and lungs' function(s) related?

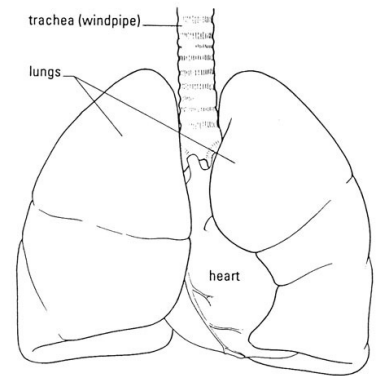


LAB - Dissection of Sheep's Pluck

Purpose: Today we will be exploring the structures of the respiratory system. We will also be examining how our lungs move as we breathe. Lastly, we will be describing how the structure of the lungs relate to how we breathe.

Procedure:

1. When handling the sheep's pluck, make sure to wear disposable gloves. Aprons and goggles are also available for additional protection.
2. Examine your specimen. Describe the color, shape, size, and feel of the specimen.
3. What organs/body parts are included in your specimen?
4. Identify the trachea. Is the trachea stiff or flexible? What allows the trachea to stay open and bend? Why is this important?
5. Try to inflate the lungs and observe how they respond. Do not breathe directly into the trachea to do this! Insert a length of rubber tubing into the trachea and attach it to a bellows or foot pump to inflate the lungs and then watch them deflate. It is best not to breathe through the tube into the lungs yourself because of the elastic recoil of the lung tissue: you might inhale a blast of rather unpleasant air!
 - a. What happened to the lungs when air was forced into them?
 - b. Do you think there is a limit to how much air can be pumped into the lungs? Explain your answer
5. Start of cut down the trachea with your dissecting scissors. Does the trachea stay as one tube or does it split as it enters the lung?



6. If the larynx is still attached to your lungs, try forcing air through the larynx while you squeeze it tight. As air moves past the skin and cords in the larynx it may make a noise.

Discuss how similar this is to the noise the animal makes in life.

7. Cut a small piece of spongy lung tissue to examine more closely.

- Are the lungs hollow bags or spongy? _____
- What does the lung tissue look like where you cut into it? _____
- Drop the piece of lung into a beaker of water. Does the piece sink or float? _____
- What does the answer to part c indicate? _____

8. Now let's examine the heart as review. Use a scalpel to remove a portion of this layer and expose the *myocardium* beneath.

- Note the abundance of fat along the paths of various blood vessels. This adipose tissue occurs in the loose connective tissue that underlies the visceral pericardium.
- Identify the following: ***Right Atrium, Right Ventricle, Pulmonary Artery, Left Atrium, Left Ventricle, and the Aorta***

9. Examine the dorsal surface of the heart (the side closest to your back).

- Locate the stumps of two relatively thin-walled blood vessels that enter the right atrium.
- Demonstrate this connection by passing a slender probe through them.
- The upper vessel is the *superior vena cava*, and the lower one is the *inferior vena cava*.

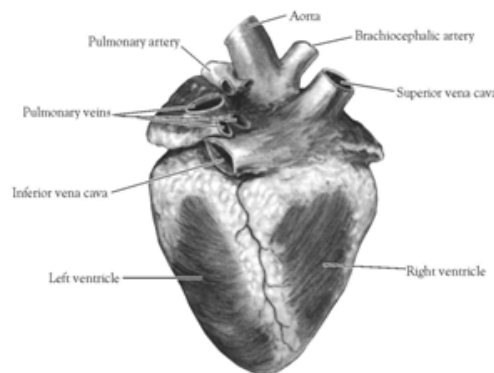


Figure 2. Heart (Posterior View)

10. Open the *right atrium*. To do this, follow these steps:

- Insert a blade of the scissors into the *superior vena cava* and cut downward through the atrial wall.
- Open the chamber, locate the *tricuspid valve* and examine its cusps.
- Run some water through the tricuspid valve to fill the chamber of the *right ventricle*.
- Gently squeeze the ventricles and watch the cusps of the valve as the water moves up against them.

11. Open the *right ventricle* as follows:

- a. Continue cutting downward through the *tricuspid valve* and the *right ventricular wall* until you reach the apex of the heart.
- b. Find the opening to the *pulmonary trunk* and use the scissors to cut upward through the wall of the *right ventricle*. Follow the pulmonary trunk until you have exposed the *pulmonary valve*.
- c. Examine the valve and its cusps.

12. Open the left side of the heart. To do this, follow these steps:

- a. Insert the blade of the scissors through the wall of the *left atrium* and cut downward to the apex of the heart.
- b. Open the *left atrium* and locate the four openings of the *pulmonary veins*. Pass a slender probe through each opening and locate the stump of its vessel.
- c. Examine the *bicuspid valve* (mitral valve) and its cusps.
- d. Also examine the *left ventricle* and compare the thickness of its wall with that of the *right ventricle*.

13. Locate the *aorta*, which leads away from the *left ventricle*, and proceed as follows:

- a. Compare the thickness of the *aortic wall* with that of the *pulmonary trunk*.
- b. Use scissors to cut along the length of the *aorta* to expose the *aortic valve* at its base.
- c. Examine the cusps of the valve and locate the openings of the *coronary arteries* just distal to them.

Questions

1. How many chambers are found in the mammalian heart? List these chambers.
2. Which chambers are the pumping chambers of the heart?
3. Which chambers are the receiving chambers of the heart?

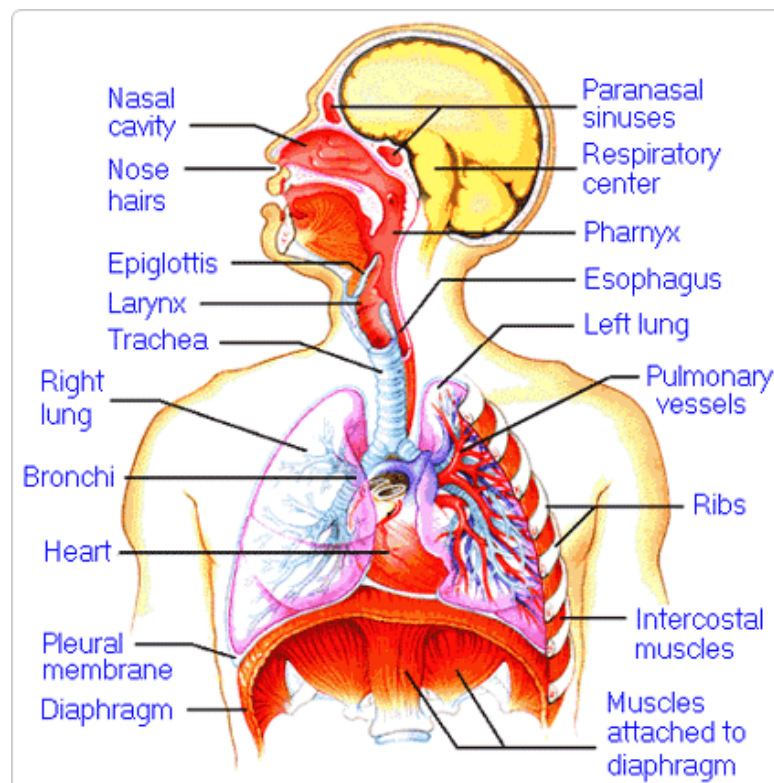
4. How do the walls of the atria compare with the walls of the ventricles and why are they different?

5. What is the purpose of heart valves?

6. Vessels that carry blood away from the heart are called _____, while _____ carry blood toward the heart.

7. Which artery is the largest and why?

8. How are the heart and lungs' function(s) related?

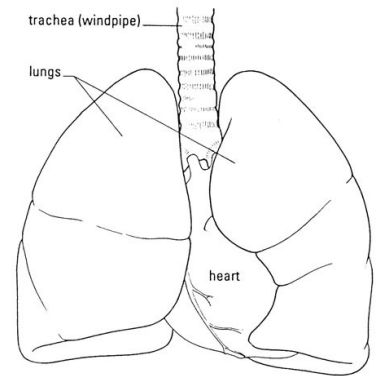


LAB - Dissection of Sheep's Pluck

Purpose: Today we will be exploring the structures of the respiratory system. We will also be examining how our lungs move as we breathe. Lastly, we will be describing how the structure of the lungs relate to how we breathe.

Procedure:

1. When handling the sheep's pluck, make sure to wear disposable gloves. Aprons and goggles are also available for additional protection.
2. Examine your specimen. Describe the color, shape, size, and feel of the specimen.
3. What organs/body parts are included in your specimen?
4. Identify the trachea. Is the trachea stiff or flexible? What allows the trachea to stay open and bend? Why is this important?
5. Try to inflate the lungs and observe how they respond. Do not breathe directly into the trachea to do this! Insert a length of rubber tubing into the trachea and attach it to a bellows or foot pump to inflate the lungs and then watch them deflate. It is best not to breathe through the tube into the lungs yourself because of the elastic recoil of the lung tissue: you might inhale a blast of rather unpleasant air!
 - a. What happened to the lungs when air was forced into them?
 - b. Do you think there is a limit to how much air can be pumped into the lungs? Explain your answer
5. Start of cut down the trachea with your dissecting scissors. Does the trachea stay as one tube or does it split as it enters the lung?



6. If the larynx is still attached to your lungs, try forcing air through the larynx while you squeeze it tight. As air moves past the skin and cords in the larynx it may make a noise.

Discuss how similar this is to the noise the animal makes in life.

7. Cut a small piece of spongy lung tissue to examine more closely.

- Are the lungs hollow bags or spongy? _____
- What does the lung tissue look like where you cut into it? _____
- Drop the piece of lung into a beaker of water. Does the piece sink or float? _____
- What does the answer to part c indicate? _____

8. Now let's examine the heart as review. Use a scalpel to remove a portion of this layer and expose the *myocardium* beneath.

- Note the abundance of fat along the paths of various blood vessels. This adipose tissue occurs in the loose connective tissue that underlies the visceral pericardium.
- Identify the following: ***Right Atrium, Right Ventricle, Pulmonary Artery, Left Atrium, Left Ventricle, and the Aorta***

9. Examine the dorsal surface of the heart (the side closest to your back).

- Locate the stumps of two relatively thin-walled blood vessels that enter the right atrium.
- Demonstrate this connection by passing a slender probe through them.
- The upper vessel is the *superior vena cava*, and the lower one is the *inferior vena cava*.

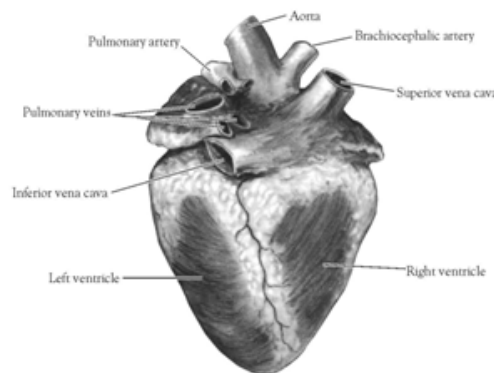


Figure 2. Heart (Posterior View)

10. Open the *right atrium*. To do this, follow these steps:

- Insert a blade of the scissors into the *superior vena cava* and cut downward through the atrial wall.
- Open the chamber, locate the *tricuspid valve* and examine its cusps.
- Run some water through the tricuspid valve to fill the chamber of the *right ventricle*.
- Gently squeeze the ventricles and watch the cusps of the valve as the water moves up against them.

11. Open the *right ventricle* as follows:

- a. Continue cutting downward through the *tricuspid valve* and the *right ventricular wall* until you reach the apex of the heart.
- b. Find the opening to the *pulmonary trunk* and use the scissors to cut upward through the wall of the *right ventricle*. Follow the pulmonary trunk until you have exposed the *pulmonary valve*.
- c. Examine the valve and its cusps.

12. Open the left side of the heart. To do this, follow these steps:

- a. Insert the blade of the scissors through the wall of the *left atrium* and cut downward to the apex of the heart.
- b. Open the *left atrium* and locate the four openings of the *pulmonary veins*. Pass a slender probe through each opening and locate the stump of its vessel.
- c. Examine the *bicuspid valve* (mitral valve) and its cusps.
- d. Also examine the *left ventricle* and compare the thickness of its wall with that of the *right ventricle*.

13. Locate the *aorta*, which leads away from the *left ventricle*, and proceed as follows:

- a. Compare the thickness of the *aortic wall* with that of the *pulmonary trunk*.
- b. Use scissors to cut along the length of the *aorta* to expose the *aortic valve* at its base.
- c. Examine the cusps of the valve and locate the openings of the *coronary arteries* just distal to them.

Questions

1. How many chambers are found in the mammalian heart? List these chambers.
2. Which chambers are the pumping chambers of the heart?
3. Which chambers are the receiving chambers of the heart?

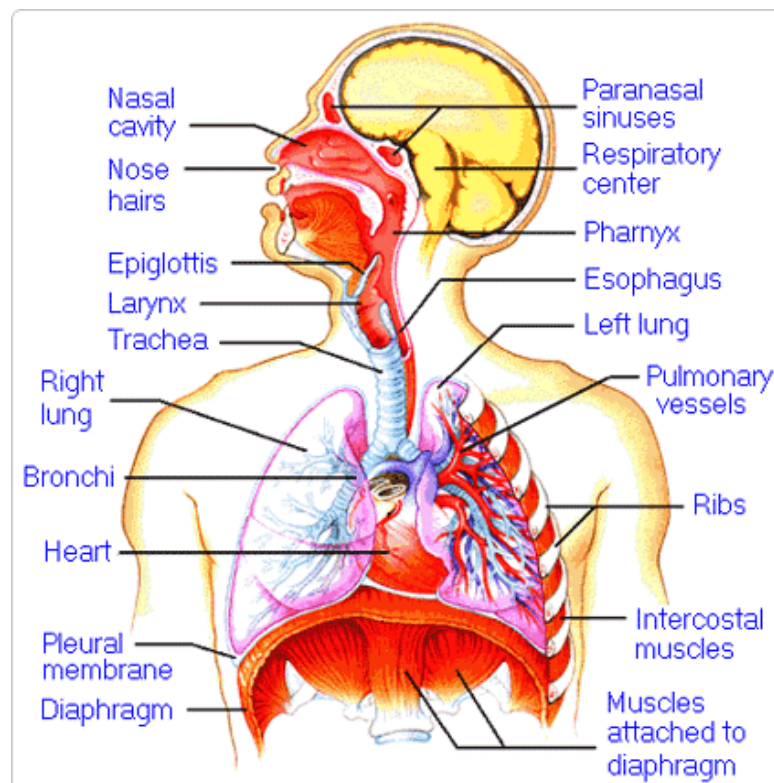
4. How do the walls of the atria compare with the walls of the ventricles and why are they different?

5. What is the purpose of heart valves?

6. Vessels that carry blood away from the heart are called _____, while _____ carry blood toward the heart.

7. Which artery is the largest and why?

8. How are the heart and lungs' function(s) related?

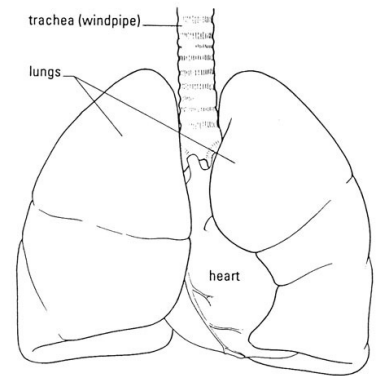


LAB - Dissection of Sheep's Pluck

Purpose: Today we will be exploring the structures of the respiratory system. We will also be examining how our lungs move as we breathe. Lastly, we will be describing how the structure of the lungs relate to how we breathe.

Procedure:

1. When handling the sheep's pluck, make sure to wear disposable gloves. Aprons and goggles are also available for additional protection.
2. Examine your specimen. Describe the color, shape, size, and feel of the specimen.
3. What organs/body parts are included in your specimen?
4. Identify the trachea. Is the trachea stiff or flexible? What allows the trachea to stay open and bend? Why is this important?
5. Try to inflate the lungs and observe how they respond. Do not breathe directly into the trachea to do this! Insert a length of rubber tubing into the trachea and attach it to a bellows or foot pump to inflate the lungs and then watch them deflate. It is best not to breathe through the tube into the lungs yourself because of the elastic recoil of the lung tissue: you might inhale a blast of rather unpleasant air!
 - a. What happened to the lungs when air was forced into them?
 - b. Do you think there is a limit to how much air can be pumped into the lungs? Explain your answer
5. Start of cut down the trachea with your dissecting scissors. Does the trachea stay as one tube or does it split as it enters the lung?



6. If the larynx is still attached to your lungs, try forcing air through the larynx while you squeeze it tight. As air moves past the skin and cords in the larynx it may make a noise.

Discuss how similar this is to the noise the animal makes in life.

7. Cut a small piece of spongy lung tissue to examine more closely.

- Are the lungs hollow bags or spongy? _____
- What does the lung tissue look like where you cut into it? _____
- Drop the piece of lung into a beaker of water. Does the piece sink or float? _____
- What does the answer to part c indicate? _____

8. Now let's examine the heart as review. Use a scalpel to remove a portion of this layer and expose the *myocardium* beneath.

- Note the abundance of fat along the paths of various blood vessels. This adipose tissue occurs in the loose connective tissue that underlies the visceral pericardium.
- Identify the following: ***Right Atrium, Right Ventricle, Pulmonary Artery, Left Atrium, Left Ventricle, and the Aorta***

9. Examine the dorsal surface of the heart (the side closest to your back).

- Locate the stumps of two relatively thin-walled blood vessels that enter the right atrium.
- Demonstrate this connection by passing a slender probe through them.
- The upper vessel is the *superior vena cava*, and the lower one is the *inferior vena cava*.

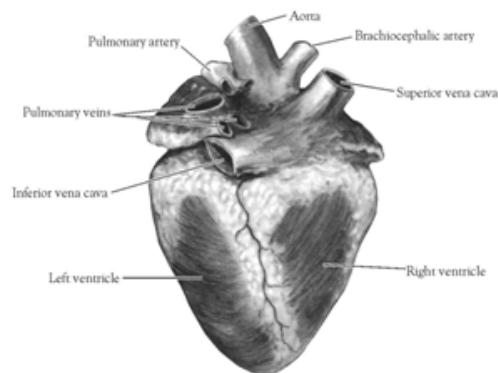


Figure 2. Heart (Posterior View)

10. Open the *right atrium*. To do this, follow these steps:

- Insert a blade of the scissors into the *superior vena cava* and cut downward through the atrial wall.
- Open the chamber, locate the *tricuspid valve* and examine its cusps.
- Run some water through the tricuspid valve to fill the chamber of the *right ventricle*.
- Gently squeeze the ventricles and watch the cusps of the valve as the water moves up against them.

11. Open the *right ventricle* as follows:

- a. Continue cutting downward through the *tricuspid valve* and the *right ventricular wall* until you reach the apex of the heart.
- b. Find the opening to the *pulmonary trunk* and use the scissors to cut upward through the wall of the *right ventricle*. Follow the pulmonary trunk until you have exposed the *pulmonary valve*.
- c. Examine the valve and its cusps.

12. Open the left side of the heart. To do this, follow these steps:

- a. Insert the blade of the scissors through the wall of the *left atrium* and cut downward to the apex of the heart.
- b. Open the *left atrium* and locate the four openings of the *pulmonary veins*. Pass a slender probe through each opening and locate the stump of its vessel.
- c. Examine the *bicuspid valve* (mitral valve) and its cusps.
- d. Also examine the *left ventricle* and compare the thickness of its wall with that of the *right ventricle*.

13. Locate the *aorta*, which leads away from the *left ventricle*, and proceed as follows:

- a. Compare the thickness of the *aortic wall* with that of the *pulmonary trunk*.
- b. Use scissors to cut along the length of the *aorta* to expose the *aortic valve* at its base.
- c. Examine the cusps of the valve and locate the openings of the *coronary arteries* just distal to them.

Questions

1. How many chambers are found in the mammalian heart? List these chambers.
2. Which chambers are the pumping chambers of the heart?
3. Which chambers are the receiving chambers of the heart?

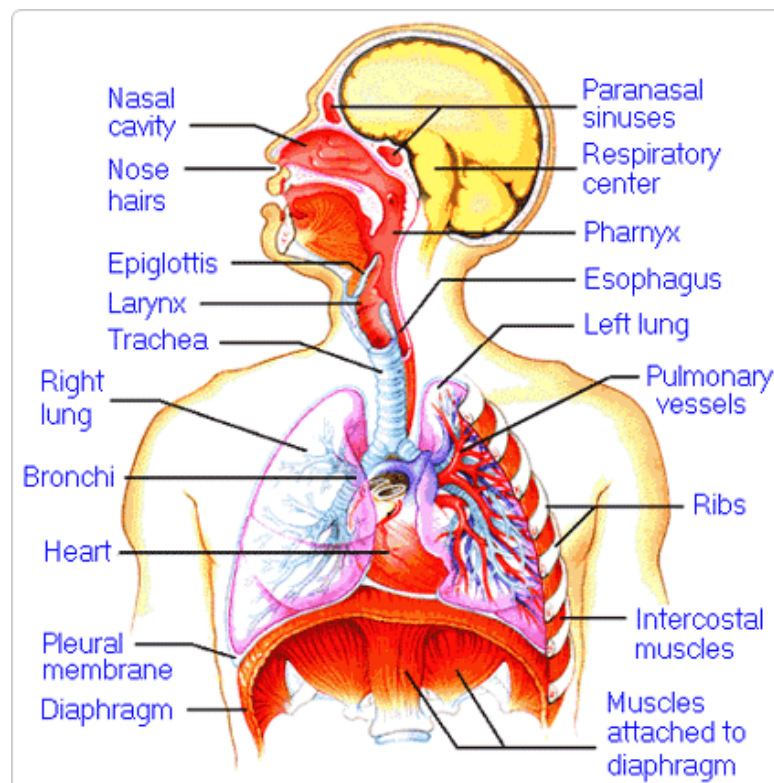
4. How do the walls of the atria compare with the walls of the ventricles and why are they different?

5. What is the purpose of heart valves?

6. Vessels that carry blood away from the heart are called _____, while _____ carry blood toward the heart.

7. Which artery is the largest and why?

8. How are the heart and lungs' function(s) related?

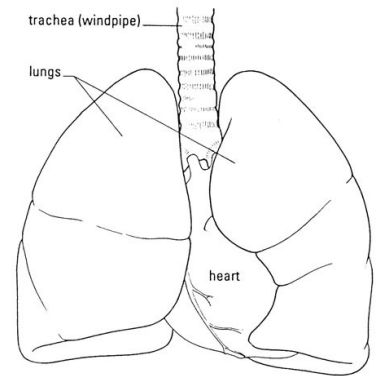


LAB - Dissection of Sheep's Pluck

Purpose: Today we will be exploring the structures of the respiratory system. We will also be examining how our lungs move as we breathe. Lastly, we will be describing how the structure of the lungs relate to how we breathe.

Procedure:

1. When handling the sheep's pluck, make sure to wear disposable gloves. Aprons and goggles are also available for additional protection.
2. Examine your specimen. Describe the color, shape, size, and feel of the specimen.
3. What organs/body parts are included in your specimen?
4. Identify the trachea. Is the trachea stiff or flexible? What allows the trachea to stay open and bend? Why is this important?
5. Try to inflate the lungs and observe how they respond. Do not breathe directly into the trachea to do this! Insert a length of rubber tubing into the trachea and attach it to a bellows or foot pump to inflate the lungs and then watch them deflate. It is best not to breathe through the tube into the lungs yourself because of the elastic recoil of the lung tissue: you might inhale a blast of rather unpleasant air!
 - a. What happened to the lungs when air was forced into them?
 - b. Do you think there is a limit to how much air can be pumped into the lungs? Explain your answer
5. Start of cut down the trachea with your dissecting scissors. Does the trachea stay as one tube or does it split as it enters the lung?



6. If the larynx is still attached to your lungs, try forcing air through the larynx while you squeeze it tight. As air moves past the skin and cords in the larynx it may make a noise.

Discuss how similar this is to the noise the animal makes in life.

7. Cut a small piece of spongy lung tissue to examine more closely.

- Are the lungs hollow bags or spongy? _____
- What does the lung tissue look like where you cut into it? _____
- Drop the piece of lung into a beaker of water. Does the piece sink or float? _____
- What does the answer to part c indicate? _____

8. Now let's examine the heart as review. Use a scalpel to remove a portion of this layer and expose the *myocardium* beneath.

- Note the abundance of fat along the paths of various blood vessels. This adipose tissue occurs in the loose connective tissue that underlies the visceral pericardium.
- Identify the following: ***Right Atrium, Right Ventricle, Pulmonary Artery, Left Atrium, Left Ventricle, and the Aorta***

9. Examine the dorsal surface of the heart (the side closest to your back).

- Locate the stumps of two relatively thin-walled blood vessels that enter the right atrium.
- Demonstrate this connection by passing a slender probe through them.
- The upper vessel is the *superior vena cava*, and the lower one is the *inferior vena cava*.

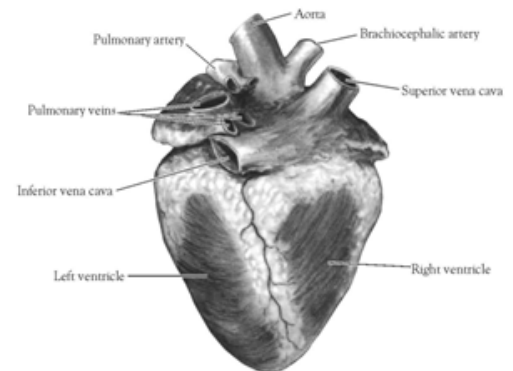


Figure 2. Heart (Posterior View)

10. Open the *right atrium*. To do this, follow these steps:

- Insert a blade of the scissors into the *superior vena cava* and cut downward through the atrial wall.
- Open the chamber, locate the *tricuspid valve* and examine its cusps.
- Run some water through the tricuspid valve to fill the chamber of the *right ventricle*.
- Gently squeeze the ventricles and watch the cusps of the valve as the water moves up against them.

11. Open the *right ventricle* as follows:

- a. Continue cutting downward through the *tricuspid valve* and the *right ventricular wall* until you reach the apex of the heart.
- b. Find the opening to the *pulmonary trunk* and use the scissors to cut upward through the wall of the *right ventricle*. Follow the pulmonary trunk until you have exposed the *pulmonary valve*.
- c. Examine the valve and its cusps.

12. Open the left side of the heart. To do this, follow these steps:

- a. Insert the blade of the scissors through the wall of the *left atrium* and cut downward to the apex of the heart.
- b. Open the *left atrium* and locate the four openings of the *pulmonary veins*. Pass a slender probe through each opening and locate the stump of its vessel.
- c. Examine the *bicuspid valve* (mitral valve) and its cusps.
- d. Also examine the *left ventricle* and compare the thickness of its wall with that of the *right ventricle*.

13. Locate the *aorta*, which leads away from the *left ventricle*, and proceed as follows:

- a. Compare the thickness of the *aortic wall* with that of the *pulmonary trunk*.
- b. Use scissors to cut along the length of the *aorta* to expose the *aortic valve* at its base.
- c. Examine the cusps of the valve and locate the openings of the *coronary arteries* just distal to them.

Questions

1. How many chambers are found in the mammalian heart? List these chambers.
2. Which chambers are the pumping chambers of the heart?
3. Which chambers are the receiving chambers of the heart?

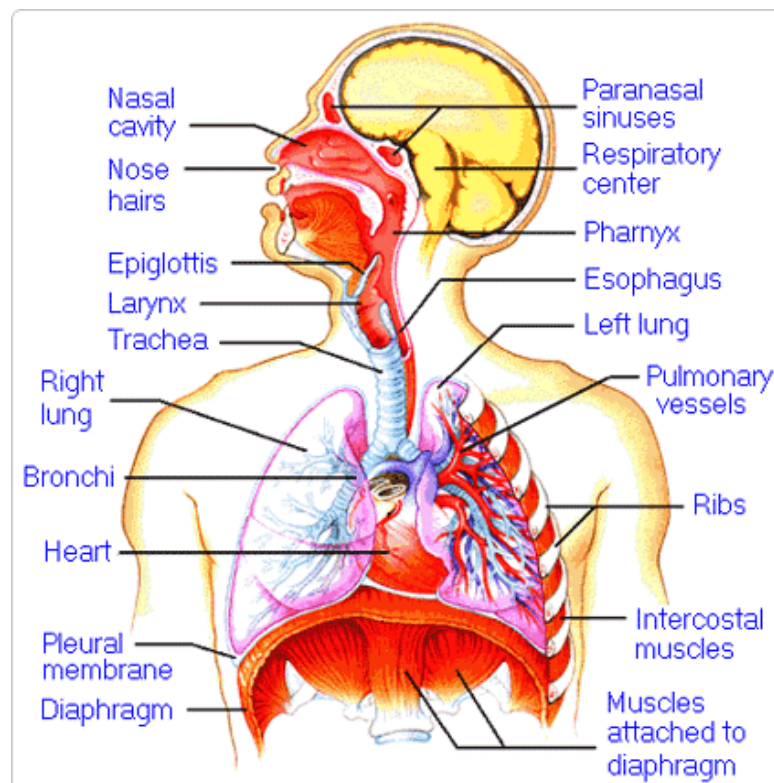
4. How do the walls of the atria compare with the walls of the ventricles and why are they different?

5. What is the purpose of heart valves?

6. Vessels that carry blood away from the heart are called _____, while _____ carry blood toward the heart.

7. Which artery is the largest and why?

8. How are the heart and lungs' function(s) related?

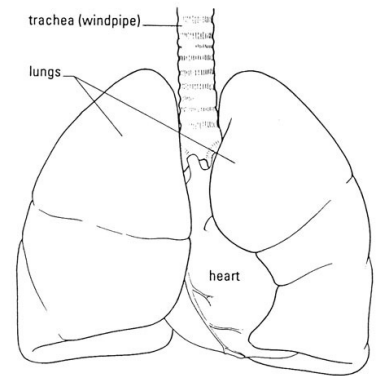


LAB - Dissection of Sheep's Pluck

Purpose: Today we will be exploring the structures of the respiratory system. We will also be examining how our lungs move as we breathe. Lastly, we will be describing how the structure of the lungs relate to how we breathe.

Procedure:

1. When handling the sheep's pluck, make sure to wear disposable gloves. Aprons and goggles are also available for additional protection.
2. Examine your specimen. Describe the color, shape, size, and feel of the specimen.
3. What organs/body parts are included in your specimen?
4. Identify the trachea. Is the trachea stiff or flexible? What allows the trachea to stay open and bend? Why is this important?
5. Try to inflate the lungs and observe how they respond. Do not breathe directly into the trachea to do this! Insert a length of rubber tubing into the trachea and attach it to a bellows or foot pump to inflate the lungs and then watch them deflate. It is best not to breathe through the tube into the lungs yourself because of the elastic recoil of the lung tissue: you might inhale a blast of rather unpleasant air!
 - a. What happened to the lungs when air was forced into them?
 - b. Do you think there is a limit to how much air can be pumped into the lungs? Explain your answer
5. Start of cut down the trachea with your dissecting scissors. Does the trachea stay as one tube or does it split as it enters the lung?



6. If the larynx is still attached to your lungs, try forcing air through the larynx while you squeeze it tight. As air moves past the skin and cords in the larynx it may make a noise.

Discuss how similar this is to the noise the animal makes in life.

7. Cut a small piece of spongy lung tissue to examine more closely.

- Are the lungs hollow bags or spongy? _____
- What does the lung tissue look like where you cut into it? _____
- Drop the piece of lung into a beaker of water. Does the piece sink or float? _____
- What does the answer to part c indicate? _____

8. Now let's examine the heart as review. Use a scalpel to remove a portion of this layer and expose the *myocardium* beneath.

- Note the abundance of fat along the paths of various blood vessels. This adipose tissue occurs in the loose connective tissue that underlies the visceral pericardium.
- Identify the following: ***Right Atrium, Right Ventricle, Pulmonary Artery, Left Atrium, Left Ventricle, and the Aorta***

9. Examine the dorsal surface of the heart (the side closest to your back).

- Locate the stumps of two relatively thin-walled blood vessels that enter the right atrium.
- Demonstrate this connection by passing a slender probe through them.
- The upper vessel is the *superior vena cava*, and the lower one is the *inferior vena cava*.

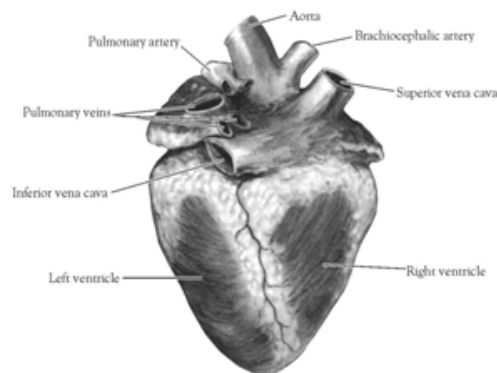


Figure 2. Heart (Posterior View)

10. Open the *right atrium*. To do this, follow these steps:

- Insert a blade of the scissors into the *superior vena cava* and cut downward through the atrial wall.
- Open the chamber, locate the *tricuspid valve* and examine its cusps.
- Run some water through the tricuspid valve to fill the chamber of the *right ventricle*.
- Gently squeeze the ventricles and watch the cusps of the valve as the water moves up against them.

11. Open the *right ventricle* as follows:

- a. Continue cutting downward through the *tricuspid valve* and the *right ventricular wall* until you reach the apex of the heart.
- b. Find the opening to the *pulmonary trunk* and use the scissors to cut upward through the wall of the *right ventricle*. Follow the pulmonary trunk until you have exposed the *pulmonary valve*.
- c. Examine the valve and its cusps.

12. Open the left side of the heart. To do this, follow these steps:

- a. Insert the blade of the scissors through the wall of the *left atrium* and cut downward to the apex of the heart.
- b. Open the *left atrium* and locate the four openings of the *pulmonary veins*. Pass a slender probe through each opening and locate the stump of its vessel.
- c. Examine the *bicuspid valve* (mitral valve) and its cusps.
- d. Also examine the *left ventricle* and compare the thickness of its wall with that of the *right ventricle*.

13. Locate the *aorta*, which leads away from the *left ventricle*, and proceed as follows:

- a. Compare the thickness of the *aortic wall* with that of the *pulmonary trunk*.
- b. Use scissors to cut along the length of the *aorta* to expose the *aortic valve* at its base.
- c. Examine the cusps of the valve and locate the openings of the *coronary arteries* just distal to them.

Questions

1. How many chambers are found in the mammalian heart? List these chambers.
2. Which chambers are the pumping chambers of the heart?
3. Which chambers are the receiving chambers of the heart?

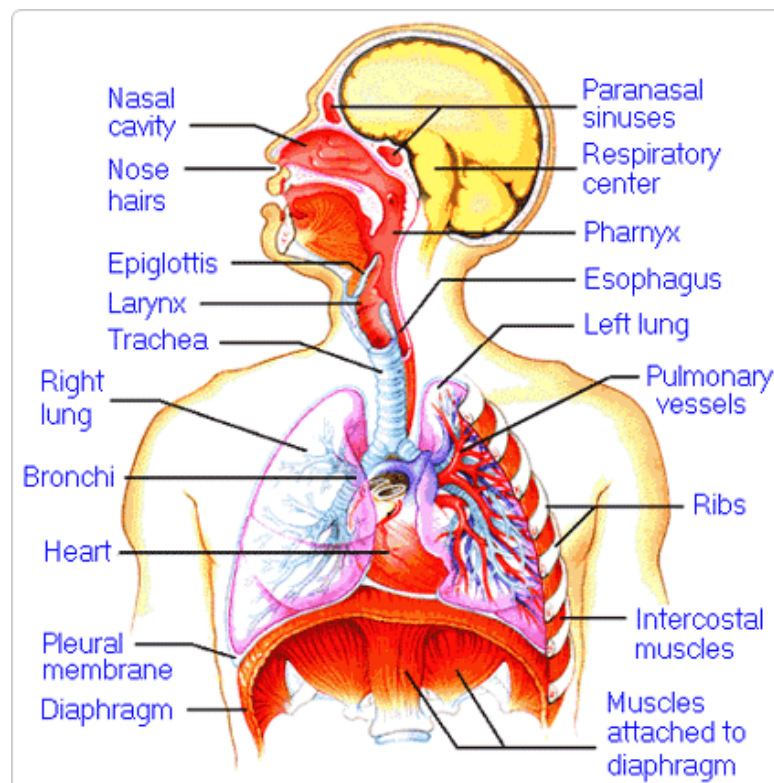
4. How do the walls of the atria compare with the walls of the ventricles and why are they different?

5. What is the purpose of heart valves?

6. Vessels that carry blood away from the heart are called _____, while _____ carry blood toward the heart.

7. Which artery is the largest and why?

8. How are the heart and lungs' function(s) related?

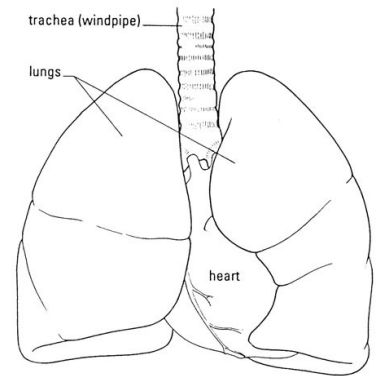


LAB - Dissection of Sheep's Pluck

Purpose: Today we will be exploring the structures of the respiratory system. We will also be examining how our lungs move as we breathe. Lastly, we will be describing how the structure of the lungs relate to how we breathe.

Procedure:

1. When handling the sheep's pluck, make sure to wear disposable gloves. Aprons and goggles are also available for additional protection.
2. Examine your specimen. Describe the color, shape, size, and feel of the specimen.
3. What organs/body parts are included in your specimen?
4. Identify the trachea. Is the trachea stiff or flexible? What allows the trachea to stay open and bend? Why is this important?
5. Try to inflate the lungs and observe how they respond. Do not breathe directly into the trachea to do this! Insert a length of rubber tubing into the trachea and attach it to a bellows or foot pump to inflate the lungs and then watch them deflate. It is best not to breathe through the tube into the lungs yourself because of the elastic recoil of the lung tissue: you might inhale a blast of rather unpleasant air!
 - a. What happened to the lungs when air was forced into them?
 - b. Do you think there is a limit to how much air can be pumped into the lungs? Explain your answer
5. Start of cut down the trachea with your dissecting scissors. Does the trachea stay as one tube or does it split as it enters the lung?



6. If the larynx is still attached to your lungs, try forcing air through the larynx while you squeeze it tight. As air moves past the skin and cords in the larynx it may make a noise.

Discuss how similar this is to the noise the animal makes in life.

7. Cut a small piece of spongy lung tissue to examine more closely.

- Are the lungs hollow bags or spongy? _____
- What does the lung tissue look like where you cut into it? _____
- Drop the piece of lung into a beaker of water. Does the piece sink or float? _____
- What does the answer to part c indicate? _____

8. Now let's examine the heart as review. Use a scalpel to remove a portion of this layer and expose the *myocardium* beneath.

- Note the abundance of fat along the paths of various blood vessels. This adipose tissue occurs in the loose connective tissue that underlies the visceral pericardium.
- Identify the following: ***Right Atrium, Right Ventricle, Pulmonary Artery, Left Atrium, Left Ventricle, and the Aorta***

9. Examine the dorsal surface of the heart (the side closest to your back).

- Locate the stumps of two relatively thin-walled blood vessels that enter the right atrium.
- Demonstrate this connection by passing a slender probe through them.
- The upper vessel is the *superior vena cava*, and the lower one is the *inferior vena cava*.

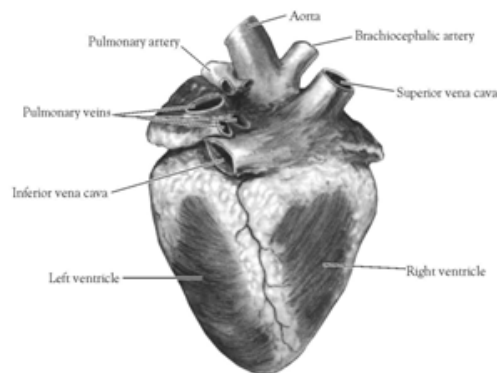


Figure 2. Heart (Posterior View)

10. Open the *right atrium*. To do this, follow these steps:

- Insert a blade of the scissors into the *superior vena cava* and cut downward through the atrial wall.
- Open the chamber, locate the *tricuspid valve* and examine its cusps.
- Run some water through the tricuspid valve to fill the chamber of the *right ventricle*.
- Gently squeeze the ventricles and watch the cusps of the valve as the water moves up against them.

11. Open the *right ventricle* as follows:

- a. Continue cutting downward through the *tricuspid valve* and the *right ventricular wall* until you reach the apex of the heart.
- b. Find the opening to the *pulmonary trunk* and use the scissors to cut upward through the wall of the *right ventricle*. Follow the pulmonary trunk until you have exposed the *pulmonary valve*.
- c. Examine the valve and its cusps.

12. Open the left side of the heart. To do this, follow these steps:

- a. Insert the blade of the scissors through the wall of the *left atrium* and cut downward to the apex of the heart.
- b. Open the *left atrium* and locate the four openings of the *pulmonary veins*. Pass a slender probe through each opening and locate the stump of its vessel.
- c. Examine the *bicuspid valve* (mitral valve) and its cusps.
- d. Also examine the *left ventricle* and compare the thickness of its wall with that of the *right ventricle*.

13. Locate the *aorta*, which leads away from the *left ventricle*, and proceed as follows:

- a. Compare the thickness of the *aortic wall* with that of the *pulmonary trunk*.
- b. Use scissors to cut along the length of the *aorta* to expose the *aortic valve* at its base.
- c. Examine the cusps of the valve and locate the openings of the *coronary arteries* just distal to them.

Questions

1. How many chambers are found in the mammalian heart? List these chambers.
2. Which chambers are the pumping chambers of the heart?
3. Which chambers are the receiving chambers of the heart?

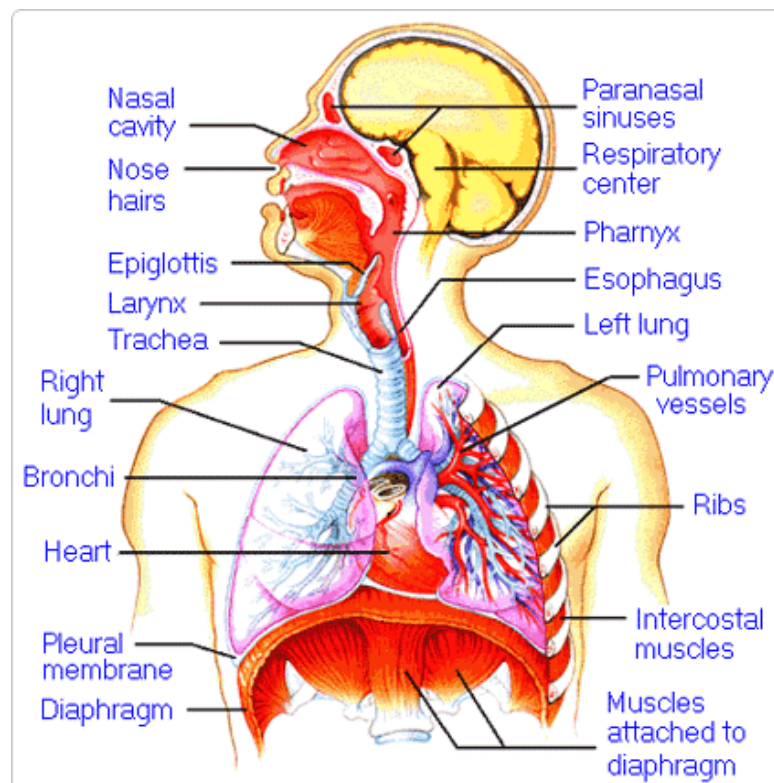
4. How do the walls of the atria compare with the walls of the ventricles and why are they different?

5. What is the purpose of heart valves?

6. Vessels that carry blood away from the heart are called _____, while _____ carry blood toward the heart.

7. Which artery is the largest and why?

8. How are the heart and lungs' function(s) related?

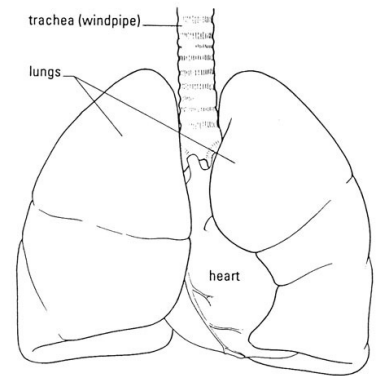


LAB - Dissection of Sheep's Pluck

Purpose: Today we will be exploring the structures of the respiratory system. We will also be examining how our lungs move as we breathe. Lastly, we will be describing how the structure of the lungs relate to how we breathe.

Procedure:

1. When handling the sheep's pluck, make sure to wear disposable gloves. Aprons and goggles are also available for additional protection.
2. Examine your specimen. Describe the color, shape, size, and feel of the specimen.
3. What organs/body parts are included in your specimen?
4. Identify the trachea. Is the trachea stiff or flexible? What allows the trachea to stay open and bend? Why is this important?
5. Try to inflate the lungs and observe how they respond. Do not breathe directly into the trachea to do this! Insert a length of rubber tubing into the trachea and attach it to a bellows or foot pump to inflate the lungs and then watch them deflate. It is best not to breathe through the tube into the lungs yourself because of the elastic recoil of the lung tissue: you might inhale a blast of rather unpleasant air!
 - a. What happened to the lungs when air was forced into them?
 - b. Do you think there is a limit to how much air can be pumped into the lungs? Explain your answer
5. Start of cut down the trachea with your dissecting scissors. Does the trachea stay as one tube or does it split as it enters the lung?



6. If the larynx is still attached to your lungs, try forcing air through the larynx while you squeeze it tight. As air moves past the skin and cords in the larynx it may make a noise.

Discuss how similar this is to the noise the animal makes in life.

7. Cut a small piece of spongy lung tissue to examine more closely.

- Are the lungs hollow bags or spongy? _____
- What does the lung tissue look like where you cut into it? _____
- Drop the piece of lung into a beaker of water. Does the piece sink or float? _____
- What does the answer to part c indicate? _____

8. Now let's examine the heart as review. Use a scalpel to remove a portion of this layer and expose the *myocardium* beneath.

- Note the abundance of fat along the paths of various blood vessels. This adipose tissue occurs in the loose connective tissue that underlies the visceral pericardium.
- Identify the following: ***Right Atrium, Right Ventricle, Pulmonary Artery, Left Atrium, Left Ventricle, and the Aorta***

9. Examine the dorsal surface of the heart (the side closest to your back).

- Locate the stumps of two relatively thin-walled blood vessels that enter the right atrium.
- Demonstrate this connection by passing a slender probe through them.
- The upper vessel is the *superior vena cava*, and the lower one is the *inferior vena cava*.

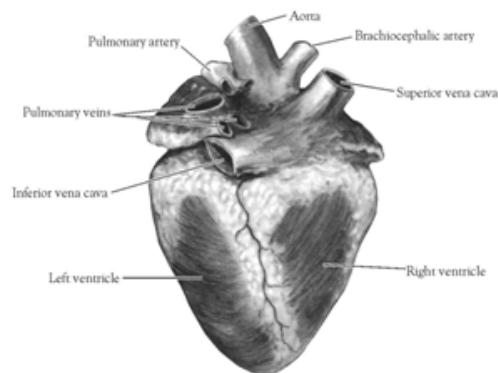


Figure 2. Heart (Posterior View)

10. Open the *right atrium*. To do this, follow these steps:

- Insert a blade of the scissors into the *superior vena cava* and cut downward through the atrial wall.
- Open the chamber, locate the *tricuspid valve* and examine its cusps.
- Run some water through the tricuspid valve to fill the chamber of the *right ventricle*.
- Gently squeeze the ventricles and watch the cusps of the valve as the water moves up against them.

11. Open the *right ventricle* as follows:

- a. Continue cutting downward through the *tricuspid valve* and the *right ventricular wall* until you reach the apex of the heart.
- b. Find the opening to the *pulmonary trunk* and use the scissors to cut upward through the wall of the *right ventricle*. Follow the pulmonary trunk until you have exposed the *pulmonary valve*.
- c. Examine the valve and its cusps.

12. Open the left side of the heart. To do this, follow these steps:

- a. Insert the blade of the scissors through the wall of the *left atrium* and cut downward to the apex of the heart.
- b. Open the *left atrium* and locate the four openings of the *pulmonary veins*. Pass a slender probe through each opening and locate the stump of its vessel.
- c. Examine the *bicuspid valve* (mitral valve) and its cusps.
- d. Also examine the *left ventricle* and compare the thickness of its wall with that of the *right ventricle*.

13. Locate the *aorta*, which leads away from the *left ventricle*, and proceed as follows:

- a. Compare the thickness of the *aortic wall* with that of the *pulmonary trunk*.
- b. Use scissors to cut along the length of the *aorta* to expose the *aortic valve* at its base.
- c. Examine the cusps of the valve and locate the openings of the *coronary arteries* just distal to them.

Questions

1. How many chambers are found in the mammalian heart? List these chambers.
2. Which chambers are the pumping chambers of the heart?
3. Which chambers are the receiving chambers of the heart?

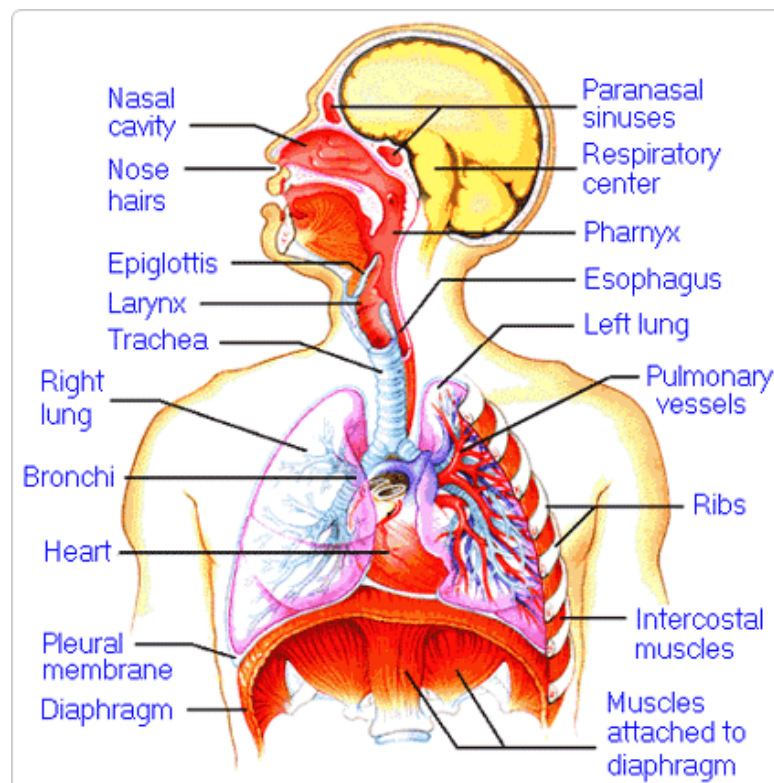
4. How do the walls of the atria compare with the walls of the ventricles and why are they different?

5. What is the purpose of heart valves?

6. Vessels that carry blood away from the heart are called _____, while _____ carry blood toward the heart.

7. Which artery is the largest and why?

8. How are the heart and lungs' function(s) related?

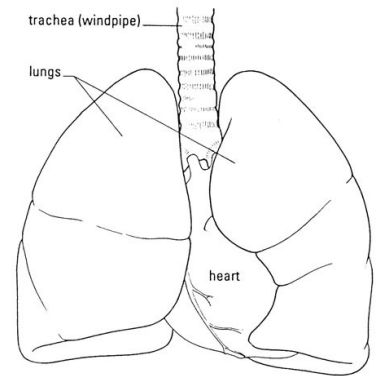


LAB - Dissection of Sheep's Pluck

Purpose: Today we will be exploring the structures of the respiratory system. We will also be examining how our lungs move as we breathe. Lastly, we will be describing how the structure of the lungs relate to how we breath.

Procedure:

1. When handling the sheep's pluck, make sure to wear disposable gloves. Aprons and goggles are also available for additional protection.
2. Examine your specimen. Describe the color, shape, size, and feel of the specimen.
3. What organs/body parts are included in your specimen?
4. Identify the trachea. Is the trachea stiff or flexible? What allows the trachea to stay open and bend? Why is this important?
5. Try to inflate the lungs and observe how they respond. Do not breathe directly into the trachea to do this! Insert a length of rubber tubing into the trachea and attach it to a bellows or foot pump to inflate the lungs and then watch them deflate. It is best not to breathe through the tube into the lungs yourself because of the elastic recoil of the lung tissue: you might inhale a blast of rather unpleasant air!
 - a. What happened to the lungs when air was forced into them?
 - b. Do you think there is a limit to how much air can be pumped into the lungs? Explain your answer
5. Start of cut down the trachea with your dissecting scissors. Does the trachea stay as one tube or does it split as it enters the lung?



6. If the larynx is still attached to your lungs, try forcing air through the larynx while you squeeze it tight. As air moves past the skin and cords in the larynx it may make a noise.

Discuss how similar this is to the noise the animal makes in life.

7. Cut a small piece of spongy lung tissue to examine more closely.

- Are the lungs hollow bags or spongy? _____
- What does the lung tissue look like where you cut into it? _____
- Drop the piece of lung into a beaker of water. Does the piece sink or float? _____
- What does the answer to part c indicate? _____

8. Now let's examine the heart as review. Use a scalpel to remove a portion of this layer and expose the *myocardium* beneath.

- Note the abundance of fat along the paths of various blood vessels. This adipose tissue occurs in the loose connective tissue that underlies the visceral pericardium.
- Identify the following: ***Right Atrium, Right Ventricle, Pulmonary Artery, Left Atrium, Left Ventricle, and the Aorta***

9. Examine the dorsal surface of the heart (the side closest to your back).

- Locate the stumps of two relatively thin-walled blood vessels that enter the right atrium.
- Demonstrate this connection by passing a slender probe through them.
- The upper vessel is the *superior vena cava*, and the lower one is the *inferior vena cava*.

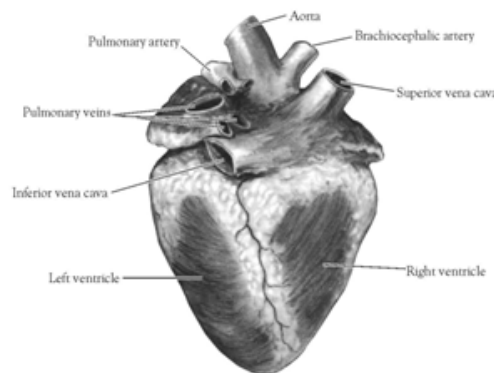


Figure 2. Heart (Posterior View)

10. Open the *right atrium*. To do this, follow these steps:

- Insert a blade of the scissors into the *superior vena cava* and cut downward through the atrial wall.
- Open the chamber, locate the *tricuspid valve* and examine its cusps.
- Run some water through the tricuspid valve to fill the chamber of the *right ventricle*.
- Gently squeeze the ventricles and watch the cusps of the valve as the water moves up against them.

11. Open the *right ventricle* as follows:

- a. Continue cutting downward through the *tricuspid valve* and the *right ventricular wall* until you reach the apex of the heart.
- b. Find the opening to the *pulmonary trunk* and use the scissors to cut upward through the wall of the *right ventricle*. Follow the pulmonary trunk until you have exposed the *pulmonary valve*.
- c. Examine the valve and its cusps.

12. Open the left side of the heart. To do this, follow these steps:

- a. Insert the blade of the scissors through the wall of the *left atrium* and cut downward to the apex of the heart.
- b. Open the *left atrium* and locate the four openings of the *pulmonary veins*. Pass a slender probe through each opening and locate the stump of its vessel.
- c. Examine the *bicuspid valve* (mitral valve) and its cusps.
- d. Also examine the *left ventricle* and compare the thickness of its wall with that of the *right ventricle*.

13. Locate the *aorta*, which leads away from the *left ventricle*, and proceed as follows:

- a. Compare the thickness of the *aortic wall* with that of the *pulmonary trunk*.
- b. Use scissors to cut along the length of the *aorta* to expose the *aortic valve* at its base.
- c. Examine the cusps of the valve and locate the openings of the *coronary arteries* just distal to them.

Questions

1. How many chambers are found in the mammalian heart? List these chambers.
2. Which chambers are the pumping chambers of the heart?
3. Which chambers are the receiving chambers of the heart?

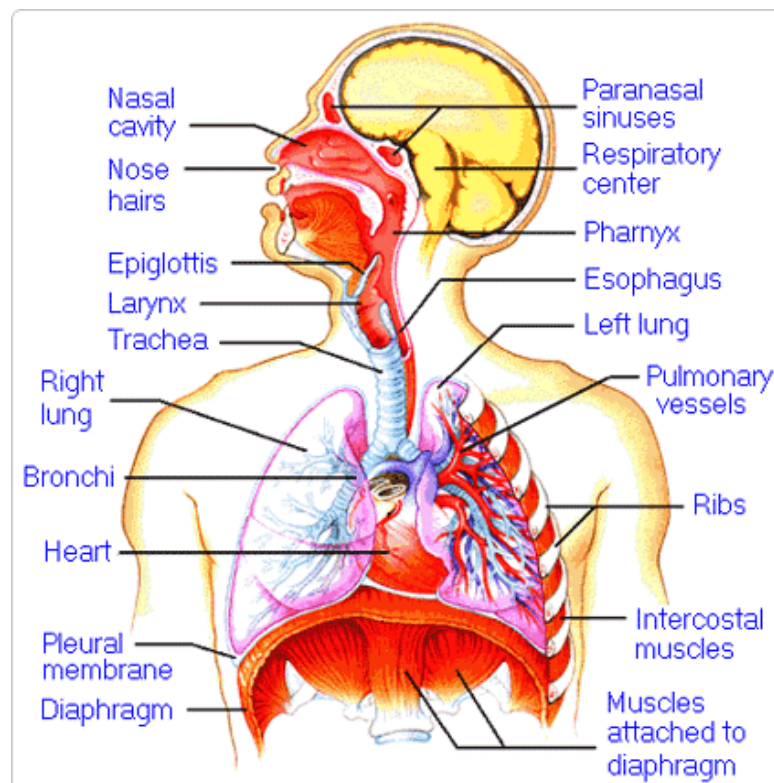
4. How do the walls of the atria compare with the walls of the ventricles and why are they different?

5. What is the purpose of heart valves?

6. Vessels that carry blood away from the heart are called _____, while _____ carry blood toward the heart.

7. Which artery is the largest and why?

8. How are the heart and lungs' function(s) related?

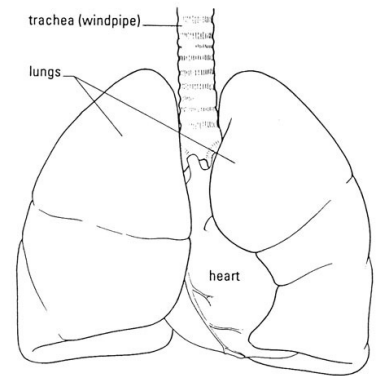


LAB - Dissection of Sheep's Pluck

Purpose: Today we will be exploring the structures of the respiratory system. We will also be examining how our lungs move as we breathe. Lastly, we will be describing how the structure of the lungs relate to how we breathe.

Procedure:

1. When handling the sheep's pluck, make sure to wear disposable gloves. Aprons and goggles are also available for additional protection.
2. Examine your specimen. Describe the color, shape, size, and feel of the specimen.
3. What organs/body parts are included in your specimen?
4. Identify the trachea. Is the trachea stiff or flexible? What allows the trachea to stay open and bend? Why is this important?
5. Try to inflate the lungs and observe how they respond. Do not breathe directly into the trachea to do this! Insert a length of rubber tubing into the trachea and attach it to a bellows or foot pump to inflate the lungs and then watch them deflate. It is best not to breathe through the tube into the lungs yourself because of the elastic recoil of the lung tissue: you might inhale a blast of rather unpleasant air!
 - a. What happened to the lungs when air was forced into them?
 - b. Do you think there is a limit to how much air can be pumped into the lungs? Explain your answer
5. Start of cut down the trachea with your dissecting scissors. Does the trachea stay as one tube or does it split as it enters the lung?



6. If the larynx is still attached to your lungs, try forcing air through the larynx while you squeeze it tight. As air moves past the skin and cords in the larynx it may make a noise.

Discuss how similar this is to the noise the animal makes in life.

7. Cut a small piece of spongy lung tissue to examine more closely.

- Are the lungs hollow bags or spongy? _____
- What does the lung tissue look like where you cut into it? _____
- Drop the piece of lung into a beaker of water. Does the piece sink or float? _____
- What does the answer to part c indicate? _____

8. Now let's examine the heart as review. Use a scalpel to remove a portion of this layer and expose the *myocardium* beneath.

- Note the abundance of fat along the paths of various blood vessels. This adipose tissue occurs in the loose connective tissue that underlies the visceral pericardium.
- Identify the following: ***Right Atrium, Right Ventricle, Pulmonary Artery, Left Atrium, Left Ventricle, and the Aorta***

9. Examine the dorsal surface of the heart (the side closest to your back).

- Locate the stumps of two relatively thin-walled blood vessels that enter the right atrium.
- Demonstrate this connection by passing a slender probe through them.
- The upper vessel is the *superior vena cava*, and the lower one is the *inferior vena cava*.

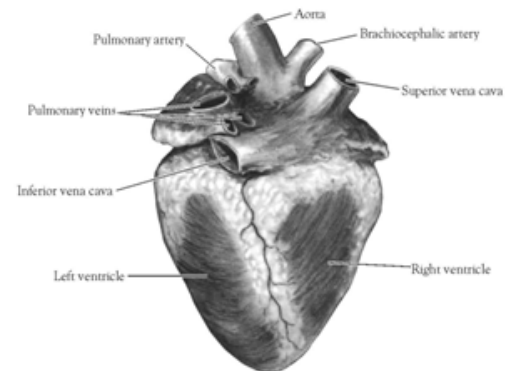


Figure 2. Heart (Posterior View)

10. Open the *right atrium*. To do this, follow these steps:

- Insert a blade of the scissors into the *superior vena cava* and cut downward through the atrial wall.
- Open the chamber, locate the *tricuspid valve* and examine its cusps.
- Run some water through the tricuspid valve to fill the chamber of the *right ventricle*.
- Gently squeeze the ventricles and watch the cusps of the valve as the water moves up against them.

11. Open the *right ventricle* as follows:

- a. Continue cutting downward through the *tricuspid valve* and the *right ventricular wall* until you reach the apex of the heart.
- b. Find the opening to the *pulmonary trunk* and use the scissors to cut upward through the wall of the *right ventricle*. Follow the pulmonary trunk until you have exposed the *pulmonary valve*.
- c. Examine the valve and its cusps.

12. Open the left side of the heart. To do this, follow these steps:

- a. Insert the blade of the scissors through the wall of the *left atrium* and cut downward to the apex of the heart.
- b. Open the *left atrium* and locate the four openings of the *pulmonary veins*. Pass a slender probe through each opening and locate the stump of its vessel.
- c. Examine the *bicuspid valve* (mitral valve) and its cusps.
- d. Also examine the *left ventricle* and compare the thickness of its wall with that of the *right ventricle*.

13. Locate the *aorta*, which leads away from the *left ventricle*, and proceed as follows:

- a. Compare the thickness of the *aortic wall* with that of the *pulmonary trunk*.
- b. Use scissors to cut along the length of the *aorta* to expose the *aortic valve* at its base.
- c. Examine the cusps of the valve and locate the openings of the *coronary arteries* just distal to them.

Questions

1. How many chambers are found in the mammalian heart? List these chambers.
2. Which chambers are the pumping chambers of the heart?
3. Which chambers are the receiving chambers of the heart?

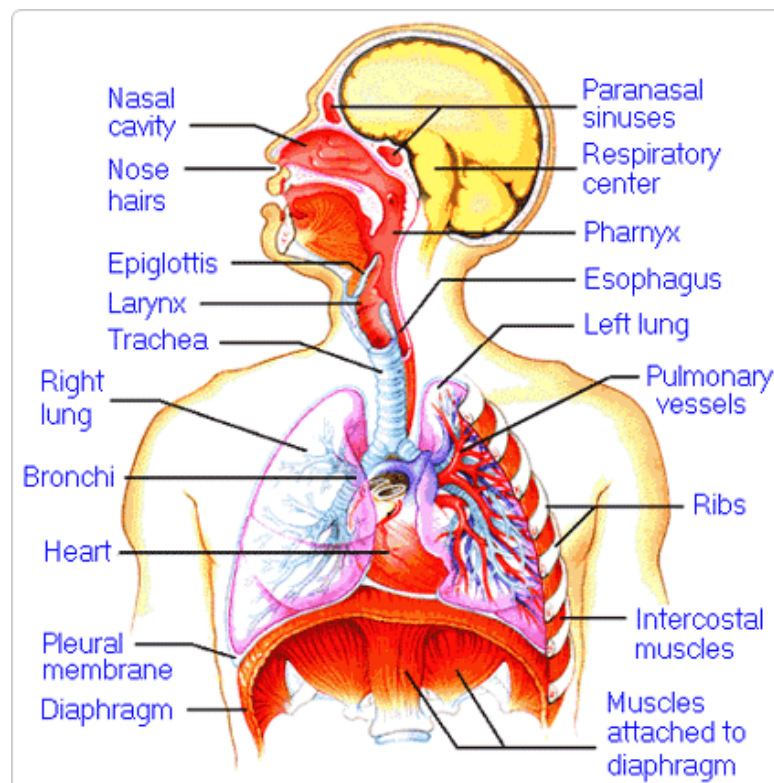
4. How do the walls of the atria compare with the walls of the ventricles and why are they different?

5. What is the purpose of heart valves?

6. Vessels that carry blood away from the heart are called _____, while _____ carry blood toward the heart.

7. Which artery is the largest and why?

8. How are the heart and lungs' function(s) related?

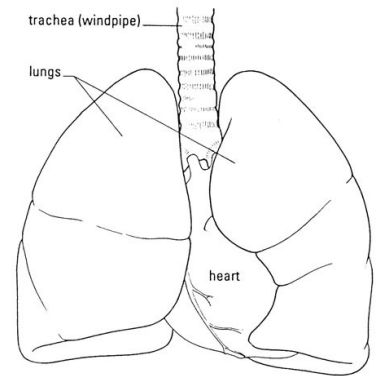


LAB - Dissection of Sheep's Pluck

Purpose: Today we will be exploring the structures of the respiratory system. We will also be examining how our lungs move as we breathe. Lastly, we will be describing how the structure of the lungs relate to how we breath.

Procedure:

1. When handling the sheep's pluck, make sure to wear disposable gloves. Aprons and goggles are also available for additional protection.
2. Examine your specimen. Describe the color, shape, size, and feel of the specimen.
3. What organs/body parts are included in your specimen?
4. Identify the trachea. Is the trachea stiff or flexible? What allows the trachea to stay open and bend? Why is this important?
5. Try to inflate the lungs and observe how they respond. Do not breathe directly into the trachea to do this! Insert a length of rubber tubing into the trachea and attach it to a bellows or foot pump to inflate the lungs and then watch them deflate. It is best not to breathe through the tube into the lungs yourself because of the elastic recoil of the lung tissue: you might inhale a blast of rather unpleasant air!
 - a. What happened to the lungs when air was forced into them?
 - b. Do you think there is a limit to how much air can be pumped into the lungs? Explain your answer
5. Start of cut down the trachea with your dissecting scissors. Does the trachea stay as one tube or does it split as it enters the lung?



6. If the larynx is still attached to your lungs, try forcing air through the larynx while you squeeze it tight. As air moves past the skin and cords in the larynx it may make a noise.

Discuss how similar this is to the noise the animal makes in life.

7. Cut a small piece of spongy lung tissue to examine more closely.

- Are the lungs hollow bags or spongy? _____
- What does the lung tissue look like where you cut into it? _____
- Drop the piece of lung into a beaker of water. Does the piece sink or float? _____
- What does the answer to part c indicate? _____

8. Now let's examine the heart as review. Use a scalpel to remove a portion of this layer and expose the *myocardium* beneath.

- Note the abundance of fat along the paths of various blood vessels. This adipose tissue occurs in the loose connective tissue that underlies the visceral pericardium.
- Identify the following: ***Right Atrium, Right Ventricle, Pulmonary Artery, Left Atrium, Left Ventricle, and the Aorta***

9. Examine the dorsal surface of the heart (the side closest to your back).

- Locate the stumps of two relatively thin-walled blood vessels that enter the right atrium.
- Demonstrate this connection by passing a slender probe through them.
- The upper vessel is the *superior vena cava*, and the lower one is the *inferior vena cava*.

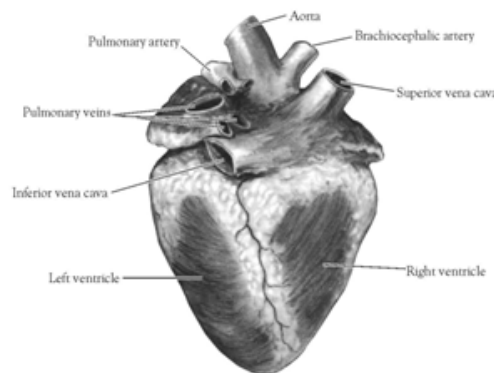


Figure 2. Heart (Posterior View)

10. Open the *right atrium*. To do this, follow these steps:

- Insert a blade of the scissors into the *superior vena cava* and cut downward through the atrial wall.
- Open the chamber, locate the *tricuspid valve* and examine its cusps.
- Run some water through the tricuspid valve to fill the chamber of the *right ventricle*.
- Gently squeeze the ventricles and watch the cusps of the valve as the water moves up against them.

11. Open the *right ventricle* as follows:

- a. Continue cutting downward through the *tricuspid valve* and the *right ventricular wall* until you reach the apex of the heart.
- b. Find the opening to the *pulmonary trunk* and use the scissors to cut upward through the wall of the *right ventricle*. Follow the pulmonary trunk until you have exposed the *pulmonary valve*.
- c. Examine the valve and its cusps.

12. Open the left side of the heart. To do this, follow these steps:

- a. Insert the blade of the scissors through the wall of the *left atrium* and cut downward to the apex of the heart.
- b. Open the *left atrium* and locate the four openings of the *pulmonary veins*. Pass a slender probe through each opening and locate the stump of its vessel.
- c. Examine the *bicuspid valve* (mitral valve) and its cusps.
- d. Also examine the *left ventricle* and compare the thickness of its wall with that of the *right ventricle*.

13. Locate the *aorta*, which leads away from the *left ventricle*, and proceed as follows:

- a. Compare the thickness of the *aortic wall* with that of the *pulmonary trunk*.
- b. Use scissors to cut along the length of the *aorta* to expose the *aortic valve* at its base.
- c. Examine the cusps of the valve and locate the openings of the *coronary arteries* just distal to them.

Questions

1. How many chambers are found in the mammalian heart? List these chambers.
2. Which chambers are the pumping chambers of the heart?
3. Which chambers are the receiving chambers of the heart?

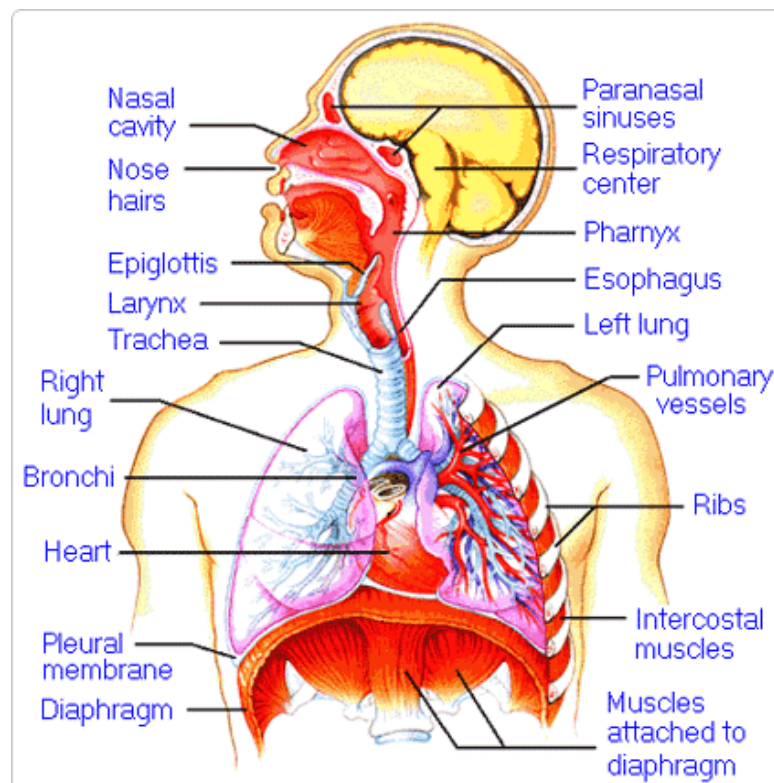
4. How do the walls of the atria compare with the walls of the ventricles and why are they different?

5. What is the purpose of heart valves?

6. Vessels that carry blood away from the heart are called _____, while _____ carry blood toward the heart.

7. Which artery is the largest and why?

8. How are the heart and lungs' function(s) related?

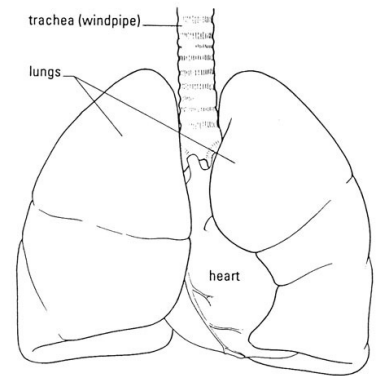


LAB - Dissection of Sheep's Pluck

Purpose: Today we will be exploring the structures of the respiratory system. We will also be examining how our lungs move as we breathe. Lastly, we will be describing how the structure of the lungs relate to how we breathe.

Procedure:

1. When handling the sheep's pluck, make sure to wear disposable gloves. Aprons and goggles are also available for additional protection.
2. Examine your specimen. Describe the color, shape, size, and feel of the specimen.
3. What organs/body parts are included in your specimen?
4. Identify the trachea. Is the trachea stiff or flexible? What allows the trachea to stay open and bend? Why is this important?
5. Try to inflate the lungs and observe how they respond. Do not breathe directly into the trachea to do this! Insert a length of rubber tubing into the trachea and attach it to a bellows or foot pump to inflate the lungs and then watch them deflate. It is best not to breathe through the tube into the lungs yourself because of the elastic recoil of the lung tissue: you might inhale a blast of rather unpleasant air!
 - a. What happened to the lungs when air was forced into them?
 - b. Do you think there is a limit to how much air can be pumped into the lungs? Explain your answer
5. Start of cut down the trachea with your dissecting scissors. Does the trachea stay as one tube or does it split as it enters the lung?



6. If the larynx is still attached to your lungs, try forcing air through the larynx while you squeeze it tight. As air moves past the skin and cords in the larynx it may make a noise.

Discuss how similar this is to the noise the animal makes in life.

7. Cut a small piece of spongy lung tissue to examine more closely.

- a. Are the lungs hollow bags or spongy? _____
- b. What does the lung tissue look like where you cut into it? _____
- c. Drop the piece of lung into a beaker of water. Does the piece sink or float? _____
- d. What does the answer to part c indicate? _____

8. Now let's examine the heart as review. Use a scalpel to remove a portion of this layer and expose the *myocardium* beneath.

- Note the abundance of fat along the paths of various blood vessels. This adipose tissue occurs in the loose connective tissue that underlies the visceral pericardium.
- Identify the following: ***Right Atrium, Right Ventricle, Pulmonary Artery, Left Atrium, Left Ventricle, and the Aorta***

9. Examine the dorsal surface of the heart (the side closest to your back).

- Locate the stumps of two relatively thin-walled blood vessels that enter the right atrium.
- Demonstrate this connection by passing a slender probe through them.
- The upper vessel is the *superior vena cava*, and the lower one is the *inferior vena cava*.

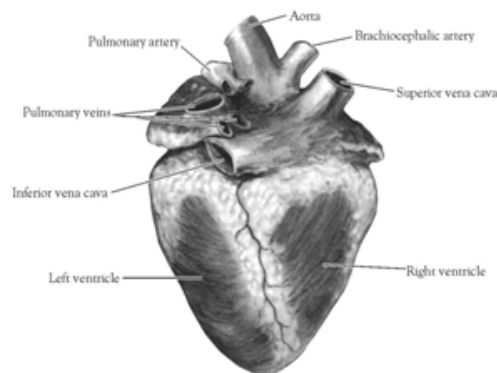


Figure 2. Heart (Posterior View)

10. Open the *right atrium*. To do this, follow these steps:

- a. Insert a blade of the scissors into the *superior vena cava* and cut downward through the atrial wall.
- b. Open the chamber, locate the *tricuspid valve* and examine its cusps.
- c. Run some water through the tricuspid valve to fill the chamber of the *right ventricle*.
- d. Gently squeeze the ventricles and watch the cusps of the valve as the water moves up against them.

11. Open the *right ventricle* as follows:

- a. Continue cutting downward through the *tricuspid valve* and the *right ventricular wall* until you reach the apex of the heart.
- b. Find the opening to the *pulmonary trunk* and use the scissors to cut upward through the wall of the *right ventricle*. Follow the pulmonary trunk until you have exposed the *pulmonary valve*.
- c. Examine the valve and its cusps.

12. Open the left side of the heart. To do this, follow these steps:

- a. Insert the blade of the scissors through the wall of the *left atrium* and cut downward to the apex of the heart.
- b. Open the *left atrium* and locate the four openings of the *pulmonary veins*. Pass a slender probe through each opening and locate the stump of its vessel.
- c. Examine the *bicuspid valve* (mitral valve) and its cusps.
- d. Also examine the *left ventricle* and compare the thickness of its wall with that of the *right ventricle*.

13. Locate the *aorta*, which leads away from the *left ventricle*, and proceed as follows:

- a. Compare the thickness of the *aortic wall* with that of the *pulmonary trunk*.
- b. Use scissors to cut along the length of the *aorta* to expose the *aortic valve* at its base.
- c. Examine the cusps of the valve and locate the openings of the *coronary arteries* just distal to them.

Questions

1. How many chambers are found in the mammalian heart? List these chambers.
2. Which chambers are the pumping chambers of the heart?
3. Which chambers are the receiving chambers of the heart?

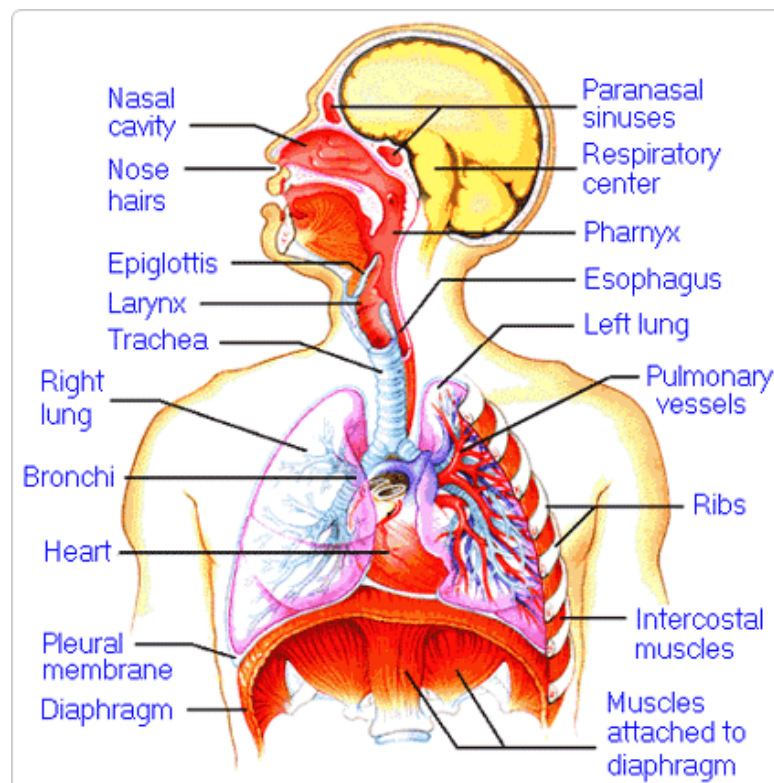
4. How do the walls of the atria compare with the walls of the ventricles and why are they different?

5. What is the purpose of heart valves?

6. Vessels that carry blood away from the heart are called _____, while _____ carry blood toward the heart.

7. Which artery is the largest and why?

8. How are the heart and lungs' function(s) related?

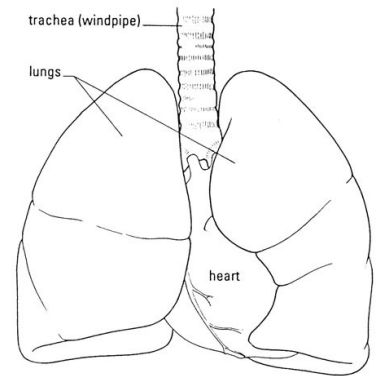


LAB - Dissection of Sheep's Pluck

Purpose: Today we will be exploring the structures of the respiratory system. We will also be examining how our lungs move as we breathe. Lastly, we will be describing how the structure of the lungs relate to how we breathe.

Procedure:

1. When handling the sheep's pluck, make sure to wear disposable gloves. Aprons and goggles are also available for additional protection.
2. Examine your specimen. Describe the color, shape, size, and feel of the specimen.
3. What organs/body parts are included in your specimen?
4. Identify the trachea. Is the trachea stiff or flexible? What allows the trachea to stay open and bend? Why is this important?
5. Try to inflate the lungs and observe how they respond. Do not breathe directly into the trachea to do this! Insert a length of rubber tubing into the trachea and attach it to a bellows or foot pump to inflate the lungs and then watch them deflate. It is best not to breathe through the tube into the lungs yourself because of the elastic recoil of the lung tissue: you might inhale a blast of rather unpleasant air!
 - a. What happened to the lungs when air was forced into them?
 - b. Do you think there is a limit to how much air can be pumped into the lungs? Explain your answer
5. Start of cut down the trachea with your dissecting scissors. Does the trachea stay as one tube or does it split as it enters the lung?



6. If the larynx is still attached to your lungs, try forcing air through the larynx while you squeeze it tight. As air moves past the skin and cords in the larynx it may make a noise.

Discuss how similar this is to the noise the animal makes in life.

7. Cut a small piece of spongy lung tissue to examine more closely.

- Are the lungs hollow bags or spongy? _____
- What does the lung tissue look like where you cut into it? _____
- Drop the piece of lung into a beaker of water. Does the piece sink or float? _____
- What does the answer to part c indicate? _____

8. Now let's examine the heart as review. Use a scalpel to remove a portion of this layer and expose the *myocardium* beneath.

- Note the abundance of fat along the paths of various blood vessels. This adipose tissue occurs in the loose connective tissue that underlies the visceral pericardium.
- Identify the following: ***Right Atrium, Right Ventricle, Pulmonary Artery, Left Atrium, Left Ventricle, and the Aorta***

9. Examine the dorsal surface of the heart (the side closest to your back).

- Locate the stumps of two relatively thin-walled blood vessels that enter the right atrium.
- Demonstrate this connection by passing a slender probe through them.
- The upper vessel is the *superior vena cava*, and the lower one is the *inferior vena cava*.

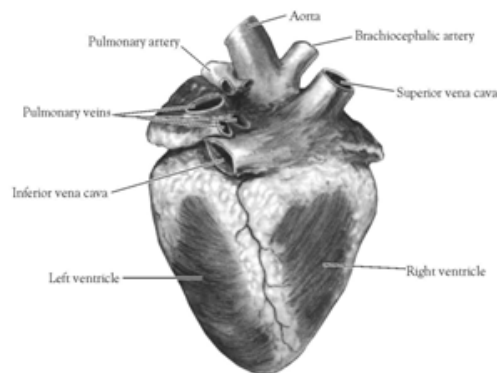


Figure 2. Heart (Posterior View)

10. Open the *right atrium*. To do this, follow these steps:

- Insert a blade of the scissors into the *superior vena cava* and cut downward through the atrial wall.
- Open the chamber, locate the *tricuspid valve* and examine its cusps.
- Run some water through the tricuspid valve to fill the chamber of the *right ventricle*.
- Gently squeeze the ventricles and watch the cusps of the valve as the water moves up against them.

11. Open the *right ventricle* as follows:

- a. Continue cutting downward through the *tricuspid valve* and the *right ventricular wall* until you reach the apex of the heart.
- b. Find the opening to the *pulmonary trunk* and use the scissors to cut upward through the wall of the *right ventricle*. Follow the pulmonary trunk until you have exposed the *pulmonary valve*.
- c. Examine the valve and its cusps.

12. Open the left side of the heart. To do this, follow these steps:

- a. Insert the blade of the scissors through the wall of the *left atrium* and cut downward to the apex of the heart.
- b. Open the *left atrium* and locate the four openings of the *pulmonary veins*. Pass a slender probe through each opening and locate the stump of its vessel.
- c. Examine the *bicuspid valve* (mitral valve) and its cusps.
- d. Also examine the *left ventricle* and compare the thickness of its wall with that of the *right ventricle*.

13. Locate the *aorta*, which leads away from the *left ventricle*, and proceed as follows:

- a. Compare the thickness of the *aortic wall* with that of the *pulmonary trunk*.
- b. Use scissors to cut along the length of the *aorta* to expose the *aortic valve* at its base.
- c. Examine the cusps of the valve and locate the openings of the *coronary arteries* just distal to them.

Questions

1. How many chambers are found in the mammalian heart? List these chambers.
2. Which chambers are the pumping chambers of the heart?
3. Which chambers are the receiving chambers of the heart?

4. How do the walls of the atria compare with the walls of the ventricles and why are they different?

5. What is the purpose of heart valves?

6. Vessels that carry blood away from the heart are called _____, while _____ carry blood toward the heart.

7. Which artery is the largest and why?

8. How are the heart and lungs' function(s) related?

